

Qualitative and Quantitative Typing of AgNORs and Expression of C-erbB-2 Oncoprotein in Hyperplastic, Dysplastic and Neoplastic Prostatic Lesions

NADIA G. EL-HEFNAWY, M.D.*; AHMAD MOHEY EL-DIN, M.D.*; NAGLAA F. ABBAS, M.D.** and TAREK EL-SHARKAWY, M.D.*

The Department of Pathology, Faculty of Medicine, Ain Shams University and National Research Center***

ABSTRACT

Purpose: In this comparative study we investigated the cell proliferation, using silver-stained nucleolar organizer regions (AgNORs) and expression of C-erbB-2 oncoprotein in benign prostatic hyperplasia (BPH), prostatic intraepithelial neoplasia (PIN) and prostatic carcinoma (PC).

Methods and results: AgNORs and C-erbB-2 expression were studied qualitatively and quantitatively in 30 prostatic specimens (10 BPH, 10 PIN and 10 PC). Lowest AgNORs counts were observed in BPH and highest counts in PC. Intermediate counts have been seen in PIN. The difference between the three groups was statistically significant ($p < 0.001$). Studying expression of C-erbB-2 oncoprotein as well as the subcellular distribution demonstrated similarity in expression of C-erbB-2 oncoprotein among high-grade PIN and PC, which differed greatly from that of BPH and low-grade PIN.

Conclusion: Our results indicate that, prostatic carcinomas may arise from prostatic intraepithelial neoplasia. Qualitative typing of AgNORs and pattern of expression of C-erbB-2 may contribute to the differential diagnosis between benign and malignant prostatic lesions. Further studies are required to highlight, the prognostic significance of C-erbB-2 in prostatic carcinomas.

Key Words: AgNORs - C-erbB-2 - Dysplastic prostatic lesions - Carcinoma.

INTRODUCTION

Nucleolar organizer regions (NORs) are loops of chromosomal DNA that ultimately direct the development of the nucleolus. These NORs are associated with argyrophilic acidic non histone proteins which have allowed the demonstration of NORs by simple silver-stain. This staining technique has been used to examine the number of silver-stained NORs (Ag-

NORs) in malignant and benign conditions and in general AgNOR numbers are increased in malignant tissues when compared with normal and benign conditions. More recently, this technique has been applied to premalignant lesions with varying results [4,12].

The C-erbB-2 proto-oncogene (also called HER-2 or neu) encodes a 185 Kda transmembrane glycoprotein [1]. It was mentioned that this protein is closely related, but yet different to EGF-receptor encoded by the C-erbB-2 proto-oncogene [6]. The structural alteration responsible for activation of C-erbB-2 gene is thought to result from a single mutation by a single amino acid substitution in the transmembrane domain [24]. Over expression of the protein product, usually associated with gene amplification, has been demonstrated in a wide range of human adenocarcinomas originated in different organs (breast, ovary, stomach, colon, lung and pancreas). For mammary and ovarian carcinomas a strong correlation between C-erbB-2 amplification and poor prognosis of the disease has been observed [25,28]. However, very little is known concerning the roles of growth factors, growth factor receptors or proto-oncogenes in the development and progression of prostatic adenocarcinomas [21].

Purpose: We examined and compared the proliferative activity (using AgNORs) and expression of C-erbB-2 oncoprotein in benign prostatic hyperplasia (BPH), prostatic intraepithelial neoplasia (PIN) and prostatic adenocarcinomas (PC).

PATIENTS AND METHODS

Prostatic tissues (30) were extracted from the files of pathology department, Ain Shams Faculty of Medicine. These specimens were obtained from patients who had undergone simple and radical prostatectomies. PIN lesions were classified into low and high grades [3,17]. PCs were graded according to WHO system in which nuclear anaplasia was used [18]. The 30 cases were classified as follows; BPH (n=10), PIN I (n=3), PIN II (n=4), PIN III (n=3) and PCs (n=10). In PIN, we preferred to evaluate PIN II and III as high-grade PIN and PIN I as low grade PIN.

AgNORs staining method:

Paraffin-embedded tissues were sectioned at 5 μ m, the sections were stained as previously described [26]. No counterstaining was used. In all cases, 50 nuclei per case were counted, using oil-immersion lens at magnification of X100. AgNORs counting and typing was done after sharp focusing on the nuclear membrane and fine granules nuclear matrix in each nucleus. Only individual AgNORs with sharp non blurred contours in this plane of focus were selected for description.

For AgNORs typing we used the typing system as previously proposed [9] (Fig. 1). The statistical analysis was performed using the student's *t* test, *p* values of less 0.05 were considered statistically significant.

Immunohistochemical staining for C-erbB-2 oncoprotein:

Additional 5- μ m tissue sections of the same blocks, used for AgNORs method were cut, mounted on slides, deparaffinized in xylene, rehydrated and soaked in tris-buffered saline for 10 minutes. The C-erbB-2 oncoprotein was demonstrated by indirect immunoperoxidase technique as described previously [21]. A monoclonal antibody specific for human C-erbB-2 was used at a concentration of 0.25 Mg/ml. Mouse immunoglobulin G (IgG) (5Mg/ml) of irrelevant specificity was used to control for monoclonal antibody specificity. The remainder of the staining procedure was performed as previously described, utilizing the Dako universal mouse kit (Dako, carpintera, calif). Breast cancer specimens were used as positive tissue controls. The slides were examined and were scored based on both the staining intensity and

the proportion of cells stained. All cases with membrane staining either alone or associated with punctate cytoplasmic staining were scored positive. Cytoplasmic staining alone was considered negative. If the staining intensity was not greater than that observed in negative controls, the specimen was assigned a score of "none". If the intensity of the stain was low, or if the intensity was strong but limited to less than 50% of the cells, the immunostaining was scored as weak. Strong staining in 50% or more was scored as moderate and strong, respectively.

RESULTS

AgNOR Scores:

AgNORs were seen nearly in all sections, lowest counts were observed in BPH (median 2.2) and highest counts in PCs (median 5.8), whereas intermediate counts have been seen in PIN (median 4.5) Table (1). The difference between three groups was statistically significant $p < 0.001$. Table (1), illustrates the difference between the three groups as regards their median values. Also, we noted a statistically significant difference ($p < 0.01$) between the three grades of PIN median values (PIN I 2.86, PIN II, 4.75, PIN III 5.73).

According to the typing system proposed by Hansen and Ostergard [9], satellite AgNORs types A₁₋₃ were predominant in BPH (Fig. 2), while types A₂ and B₁₋₂ were frequent and dominant in PIN I and types B₂₋₃ and C₁₋₂ were predominant in PIN II and III (Fig. 3) as well as in PCs (Figs. 4-6).

C-erbB-2 Oncoprotein expression:

In this study we demonstrated variation in the patterns and type of cells (luminal and basal cells), stained by monoclonal antibody specific to C-erbB-2 oncoprotein.

In BpH, 6 out of 10 specimens were stained with C-erbB-2. Three positive cases demonstrated weak immunostaining of luminal and basal cells. Two cases exhibited weak immunostaining of luminal cells (Table 2). One specimen showed moderately stained basal cells. Membranous immunostaining was predominant in 5 out of the 6 specimens (Table 3).

In low-grade PIN, weak immunostaining was observed in luminal and basal cells of all

specimens with evident equivocal cytoplasmic and membranous patterns in luminal cells (Fig. 7). However, moderate immunostaining was demonstrated in all high-grade PIN specimens and it was localized in both luminal and basal cells (3 of 7 specimens), in luminal cells only (3 of 7 specimens) and in basal cells only (one specimen) (Table 2). Both cytoplasmic and membranous immunostaining patterns were evident in 6 of 7 specimens while only one specimen showed membranous pattern (Table 3).

In PCs, moderate immunostaining for C-erbB-2 was demonstrated in 7 of 10 specimens and the remainder 3 specimens exhibited strong immunostaining. Cytoplasmic pattern was predominant in 2 out of 10 specimens (Fig. 8), while the other 8 specimens demonstrated both cytoplasmic and membranous patterns (Table 3).

Table (1): AgNOR scores of BPH, PIN and PCs.

Case Number	BPH	PIN	PCs
1	1.8	2.55	3.66
2	1.9	2.60	3.44
3	1.95	3.43	5.00
4	2.00	4.60	5.70
5	2.06	4.70	5.50
6	2.09	4.80	6.00
7	2.15	5.00	6.50
8	2.23	4.90	6.80
9	2.88	5.50	7.00
10	3.00	5.69	8.00
Mean value	2.2	4.5	5.8
SD	0.4	1.29	1.14

SD: Standard deviation.
Total No. of cases, 30.
 $p < 0.001$.

Table (2): Expression of Ce-erbB-2 oncoprotein in basal and luminal cells of BPH and PIN.

Intensity of immunostaining	BPH (n=10)			Low-grade PIN (n=3)			High-grade PIN (n=7)		
	Basal	Luminal	Both	Basal	Luminal	Both	Basal	Luminal	Both
Weak		2	3			3			
Moderate	1						1	3	3

Table (3): Patterns of positive C-erbB-2 immunostaining in BPH, PIN and PCs.

Diagnosis	Positive staining	Cytoplasmic	Membranous	Both
BPH (n=10)	6		5	1
Low-grade PIN (n=3)	3		1	2
High-grade PIN (n=7)	7		1	6
PCs (n=10)	10	2		8




Fig. (1): AgNOR typing: a satellite AgNORs: Single (A₁), Scattered (A₂), grouped (A₃); B fine granular AgNORs in nucleoli: Small (B₁) medium (B₂), large (B₃); C coarse to semi-solid AgNORs in nucleoli: small (C₁) medium (C₂), large (C₃).

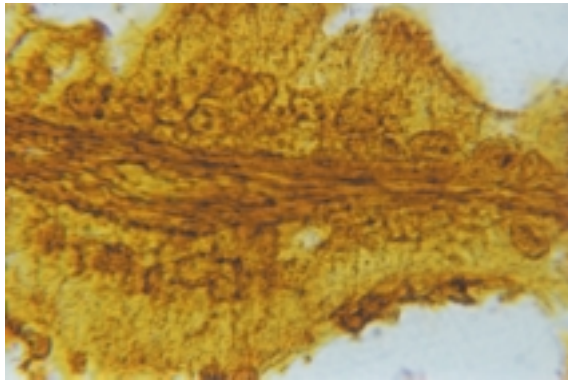


Fig. (2): Prostatic hyperplasia showing 1-2 nuclear dots (satellite AgNORs) x1000.

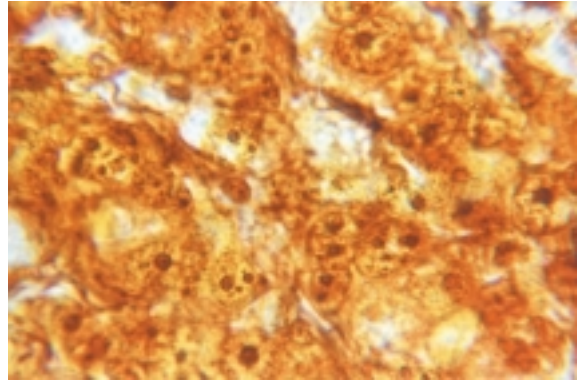


Fig. (5): Moderately differentiated prostatic adenocarcinoma showing type C₂-C₃ (i.e. coarse to semi-solid AgNORs in nucleoli)x1000.

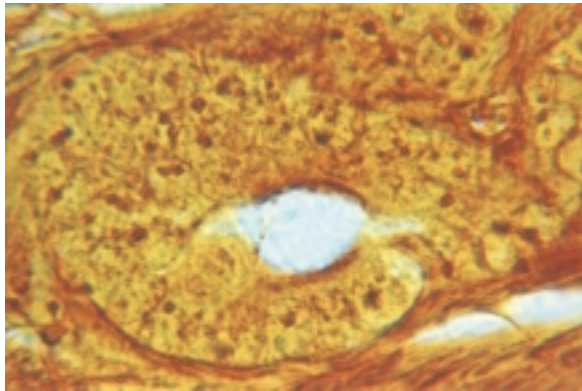


Fig. (3): Prostatic intraepithelial neoplasia grade III showing type C₁ (i.e. coarse to semisolid AgNORs in nucleoli) and type A₂ (scattered satellites x1000).

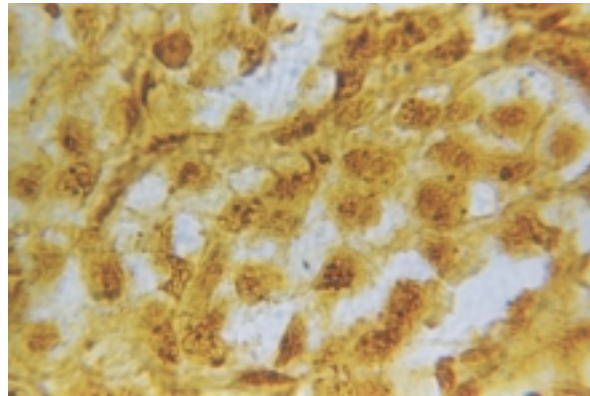


Fig. (6): Poorly differentiated prostatic adenocarcinoma showing type B₂ and scattered satellite AgNORs x1000.

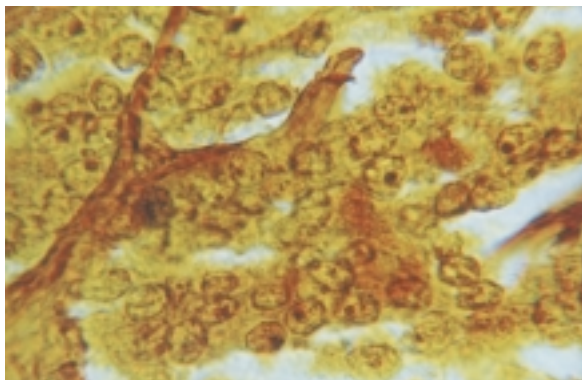


Fig. (4): Well differentiated prostatic adenocarcinoma showing type C₂ (i.e. medium sized coarse to semi-solid AgNORs in nucleoli) x1000.

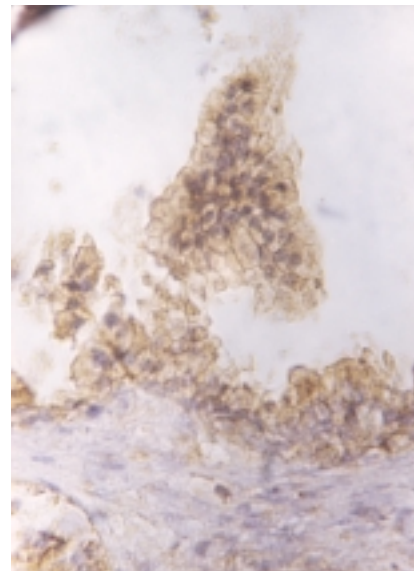


Fig. (7): Immunohistochemical demonstration of C-erbB-2 oncoprotein in low grade PIN. Note weak and predominant membranous immunostaining in both basal and luminal cells (x400).

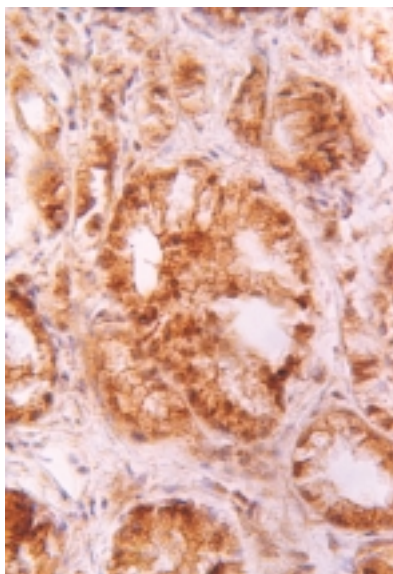


Fig. (8): Immunostaining of C-erbB-2 oncoprotein in moderately differentiated prostatic adenocarcinoma. Note predominant cytoplasmic immunostaining pattern (x400).

DISCUSSION

The grading of PIN as previously defined [17] and the WHO grading system for PCs [18], takes nuclear features into account, the total number of AgNORs has been shown to correlate with other methods of analysis of cellular proliferative activity and ploidy such as Ki67 immunostaining [23], DNA flow cytometry [8] in breast carcinoma. Also, nuclear DNA ploidy status and AgNORs has been used to predict the biologic behaviour of prostatic adenocarcinoma [20]. However, in this comparative study, we investigated, expressions of both AgNORs and proto-oncogene product (C-erbB-2) in BPH, PIN and PCs.

In the present study, we applied the one step silver nitrate method as previously described [26], to prostatic lesions, we observed a significant difference in AgNORs counts per nucleus, among BPH, PIN and PCs, this finding is consistent with other authors [7,9] who stated that NORs have prognostic significance in PCs. They found that NORs were significantly increased in malignant prostatic tissue compared to benign. NORs were significantly increased in patients destined to develop metastasis. They concluded that AgNORs may be useful as a predictor of disease outcome. Other several studies [9,11,19] have reported that AgNOR analysis revealed low values in BPH, moderate values in

low-grade carcinomas and high values in PIN as well as high grade carcinomas. The similarities of nucleolar and AgNOR analysis between PIN and high-grade carcinomas support the idea that PIN is the precursor of the peripheral prostatic carcinoma [2]. However, in contrast to the previous studies, others [4] found no significant difference in AgNORs counts in BPH, PIN and PCs. They concluded that AgNORs counts are of no use in differentiation of these lesions. In this study we also concluded that AgNORs counts are of no use in diagnosis.

We applied the typing system as previously proposed [9]. This typing system was advised to include two important features of NORs, namely size as previously pointed out [22] and degree of nucleolar disaggregation as stressed in previous reports [5,27]. Satellite AgNORs predominated in BPH, while medium-sized nucleoli with granular AgNORs predominated in PIN lesions. Large nucleoli with granular AgNORs were more frequently seen in PCs. It is concluded that qualitative typing of AgNORs may contribute to the differential diagnosis between benign and malignant prostatic lesions.

The other part of this study actually was designed for studying immunoreactivity of C-erbB-2 oncoprotein in PIN (especially high-grade PIN) and PCs. To determine the significance of C-erbB-2 in prostatic lesions (PIN and PCs), it was necessary to establish expression in BPH.

In the present study, we observed similarity between low-grade PIN and BPH concerning the pattern, distribution and intensity of immunostaining. Basal cells immunostaining and membranous patterns were frequently observed in both lesions (BPH and low-grade PIN).

A similar predominance of basal cell staining has been mentioned in a previous report [16] which localized EGF receptor to the basal cells of BpH. In a further study [21], it was stated that immunostaining for C-erbB-2 in benign glands was strongest in basal cells and it was typically absent or weak in the luminal cells and expression was localized to cell membranes. Although, the function of prostatic basal cells is unknown, it has been proposed that basal cells give rise to secretory epithelial cells and function as stem cells [21]. The proliferative potential of basal cells and their expression of various growth factor receptors and proto-oncogene

products are consistent with this hypothesis [10].

In this study moderate immunostaining for C-erbB-2 oncoprotein was observed within cytoplasm and in the membranes of luminal cells of high grade PIN and PCs. The cytoplasmic staining in prostate was more coarse and punctate than the pattern observed in breast tumours. In the prostate, pure membrane staining was unusual without concomitant cytoplasmic staining. The biological significance of cytoplasmic C-erbB-2 in malignant cells as observed by us and others [21] is unknown. Thus our findings demonstrate similarity in the expression of C-erbB-2 oncoprotein among high-grade PIN and PCs. These findings are consistent with previous reports [10,13,21].

In another report no differences in the three dimensional nuclear size was found between high grade PIN and prostatic adenocarcinoma [15] and this further supports high grade PIN as a precursor of prostatic adenocarcinoma. So, as previously concluded [14], the finding of high grade prostatic intraepithelial neoplasia in a biopsy without prostate cancer warrants repeat biopsy because of the risk of concurrent cancer.

Conclusion:

- 1- These results are suggestive that PIN is a precursor of PC.
- 2- Qualitative typing of AgNORs may contribute to the differential diagnosis between benign and malignant prostatic lesions and this needs further analysis of larger sample numbers.
- 3- Further studies are required to highlight the prognostic significance of C-erbB-2 in prostatic carcinomas.

REFERENCES

- 1- Akiyama T., Sudo C. and Ogawara: The product of the human C-erbB-2: A 185-Kilodalton glycoprotein with tyrosine kinase activity. *Science*, 232: 1644-1646, 1986.
- 2- Amin M.B., RO J.Y. and Ayala A.G.: Putative precursor lesions of prostatic adenocarcinoma: Fact or fiction. *Mod. Pathol.*, 6: 476-483, 1993.
- 3- Bostwick D.G., Amin M.B. and Dundore P.: Architectural patterns of high-grade prostatic intraepithelial neoplasia. *Hum. Pathol.*, 24: 298-310, 1993.
- 4- Cheville J.C., Clanon G.H. and Robinson R.H.: Silver-stained nucleolar organizer regions in the differentiation of prostatic hyperplasia, intraepithelial neoplasia and adenocarcinoma. *Mod. Pathol.*, 3: 596-600, 1990.
- 5- Crocker J. and Nar P.: Nucleolar organizer regions in lymphoma. *J. Pathol.*, 151: 111-118, 1987.
- 6- Dougall W.C., Qian X. and Peterson N.C.: The neu-oncogene, signal transduction pathways, transformation mechanisms and evolving therapies. *Oncogene*, 9: 2109-2123, 1994.
- 7- Gillen P., Grace P.A. and Dervan P.: Nucleolar organizer regions as predictors of outcome in prostatic carcinoma, *World. J. Urol.*, 8: 175-178, 1990.
- 8- Giri D.D., Lawry J., Dundas S.A.C. and Underwood J.C.E.: Silver binding nuclear organizer regions (AGNORs) in benign and malignant breast lesions correlation with ploidy and growth phase by DNA flow cytometry. *J. Pathol.*, 157: 307-313, 1989.
- 9- Hansen A.B. and Ostergard B.: Nucleolar organizer regions in hyperplastic and neoplastic prostatic tissue. *Virchows Archiv A Pathol. Anat.*, 417: 9-13, 1990.
- 10- Harper M.E., Glynne-Jones E., Goddard L., Matthews P. and Nicholson R.I.: Expression of androgen receptor growth factors in premalignant lesions of the prostate *J. Pathol.*, 186: 169-177, 1998.
- 11- Helpap B.: Cell kinetic studies on prostatic intraepithelial neoplasia (PIN) and atypical adenomatous hyperplasia (AAH) of the prostate. *Pathol. Res. Pract.*, 191 (9): 904-907, 1995.
- 12- Helpap B. and Riede C.: Nucleolar and AgNOR-analysis of prostatic intraepithelial neoplasia (PIN), atypical adenomatous hyperplasia (AAH) and prostatic carcinoma. *Pathol. Res. Pract.*, 191: 381-390, 1995.
- 13- Ibrahim G.K., Kerns B.J.M. and MacDonald J.A.: Differential immunoreactivity of epidermal growth factor receptor in benign, dysplastic and malignant prostatic tissues. *J. Urol.*, 149: 170-173, 1993.
- 14- Kamoi K., Tronosco P. and Babaian R.J.: Strategy for repeat biopsy in patients with high grade prostatic intraepithelial neoplasia. *J. Urol.*, 163 (3): 819-23, 2000.
- 15- Lopez Beltran A., Artacho Perula F., Roldan Villa Lobos R. and Lague Barona R.: Nuclear volume estimates in prostatic intraepithelial neoplasia. *Anal. Quant. Cytol. Histol.*, 22 (11): 37-44, 2000.

- 16- Maygarden S.J., Strom S. and Ware J.L.: Localization of epidermal growth factor receptor by immunohistochemical methods in human prostatic carcinoma, prostatic intraepithelial neoplasia and benign hyperplasia Arch. Pathol. Lab. Med., 116: 269-273, 1992.
- 17- McNeal J.E. and Bostwick D.G.: Intraductal dysplasia: a premalignant lesion of the prostate. Hum. Pathol., 17: 64-71, 1986.
- 18- Mostofi F.K., Sesterhenn I. and Sobin L.H.: Histological typing of prostate tumors. World Health Organization, Geneva, 22, 1980.
- 19- Mukher Jee J., Misra V., Gupta S.C., Gupta A.K. and Tandon S.P.: Argyrophilic nucleolar organizer regions in atypical adenomatous hyperplasia, prostatic intraepithelial neoplasias and prostatic neoplasms. Urol. Int., 58 (2): 75-9, 1997.
- 20- Murad M., El-Hosseiny S., Anwar M., Mosaad M., Tharwat W. and Eissa S.: Value of histologic grading nuclear DNA ploidy status and nucleolar organizer regions (AgNORs) count in predicting the biologic behaviour of prostatic adenocarcinoma J. of Egyptian, Nat. Cancer Inst., 8 (1): 89-96, 1996.
- 21- Myers R.B., Srivastava S., Oelschlager D.K. and Grizzle W.E.: Expression of P 160^{erbB-3} and P 185^{erbB-2} in prostatic intraepithelial neoplasia and prostatic adenocarcinoma. J. Natl Cancer Inst., 86: 1140-1145, 1994.
- 22- Ooms E.C.M. and Veldhu R.W.: Argyrophilic proteins of the nucleolar organizer regions in bladder tumors. Virchows Arch. (A), 414: 365-369, 1989.
- 23- Raymond W.A. and Leong A.S.Y.: Nucleolar organizer regions relate to growth fractions in human breast carcinomas. Hum. Pathol., 20: 741-746, 1989.
- 24- Eissa S. and Shoman S.: Specific genetic markers, Handbook of tumor Markers. First edition, Khattab Press, 7,8, 1995.
- 25- Sirvent J.J., Sanatafe M. and Salvado M.T.: Hormonal receptors cell proliferation fraction (ki-67) and C-erbB-2 amplication in breast cancer, relationship between differentiation degree and axillary lymph node metastasis, Histol. Histopathol., 9: 563-570, 1994.
- 26- Smith R. and Crocker J.: Evaluation of the nucleolar organizer region associated protein in breast malignancy. Histopathology, 12: 113-115, 1988.
- 27- Underwood J.C.E. and Giri D.D.: Nucleolar organizer regions as diagnostic discriminants for malignancy. J. Pathol., 155: 95-96, 1988.
- 28- Utrilla J.C., Lacave J.M. and San Martin M.V.: Expression of C-erbB-2 oncoprotein in thyroid tumors. Histopathology, 34: 60-65, 1999.