

Prosthetic Mesh Repair for Large Paracolostomy Hernia

HASSAN M. ABDALLA, M.D.

The Department of Surgery, NCI, Cairo University.

ABSTRACT

Paracolostomy hernias are a relatively common complication of ostomy construction. The aim of this prospective study is to determine the prevalence of paracolostomy hernia at NCI, as well as evaluation of intra-abdominal prosthetic mesh repair of Byers with some modification. The prevalence of paracolostomy hernia was 27.3%. Twenty patients underwent paracolostomy hernia repair between July 1996 and June 1999. The main outcome measures were hernia recurrence together with short and long term complications. After a mean follow-up of 26 ± 10 months, only 3 patients developed hernia recurrence. Two patients developed wound sepsis at the laparotomy incision and 2 other patients developed sepsis at ostomy site after excision of excess skin. None of them warranted mesh removal for wound infection. No other ostomy problems such as prolapse, fistulization, stenosis or retraction has resulted after successful repair. This method of paracolostomy hernia repair is technically easy and has excellent results. It is especially suitable in very large hernias.

Key Words: *Paracolostomy hernia - Mesh repair.*

INTRODUCTION

Parastomal hernia, an incisional hernia at the site of an intestinal stoma, has been a long recognized complication of stoma surgery. According to Goligher [9] some degree of herniation around a colostomy is so common that this complication may be regarded as inevitable [11]. Various studies commonly report the incidence of parastomal hernia to range from 5% to 30% [18]. However, those studies in which patients were re-examined for 5 or more years following stoma surgery have found a long-term incidence of paracolostomy hernia of 56 to 58% [10,28]. The clinical manifestation of parastomal hernia may be inconsequential and easily managed or serious and potentially life threatening. Most hernias are well tolerated and do not require repair. However, the reported series have a median repair rate of 27% [5,20]. Many techniques of parastomal hernia repair have been

described. These may be categorized broadly into fascial repair, stoma relocation and fascial repair with prosthetic material. There is no consensus regarding the optimal method of repair and there has been virtually no critical examination of the efficacy of these types of hernia repair. Thorlakson [25] recommends a direct repair via the ostomy site with closure of the defect with non absorbable suture. Goligher [9] recommends relocation of the stoma and primary closure of the fascial defect. In large hernias. Rosin and Bonardi [17] and Abdu [1] use a sheet of mesh over the fascial defect anteriorly bringing the stoma out through this mesh. Although they reported minimal complications. Sugerbaker [23] and Byers et al. [4] stated that the use of prosthetic mesh in contaminated field should be avoided. Each of them described a different technique of prosthetic repair through a peritoneal approach. This study was designed in order to evaluate the prevalence of paracolostomy hernia at NCI and to test the efficacy of intra-abdominal repair of paracolostomy hernia using polypropylene mesh and try to avoid the problems that bacterial contamination of the operative field present.

PATIENTS AND METHODS

At NCI Cairo University, a stoma care clinic was established in 1990. All patients who underwent surgery with intestinal or ureteric stoma construction were referred for follow-up and stoma care. Patients operated on before this date have also been referred.

Twenty patients with paracolostomy hernia underwent repair at NCI, Cairo University, from July 1996 to June 1999. The patient's age, sex, original ostomy operation, length of hospitalization, estimated blood loss at operation,

follow-up, complications and hernia recurrence were recorded. Risk factors for hernia recurrence, including chronic cough, poor nutrition, obesity and infection, were evaluated.

Eligibility for inclusion:

- 1- The hernia constitutes an impediment to the proper care of the stoma.
- 2- Large hernia constitutes an unacceptable cosmetic problem (> 6 cm).
- 3- Two years disease free is an important prerequisite for hernia repair.
- 4- Previous radiotherapy and/or chemotherapy is not contraindication for repair.

Excluded from this study were patients in whom the stoma was performed as a palliative management for advanced cancer, patients who had metastatic disease, as well as patients with respiratory disease with chronic cough. Hernias through the laparotomy scar near to colostomy were also excluded, because it was impossible to determine the exact origin of the hernia in these cases. Age and obesity were not absolute contraindications.

Hernia repair technique:

In this study intraperitoneal approach for repair using polypropylene mesh (Byers technique) with some modification was adopted:

- 1- Patients received a clear liquid diet for 2 days and were subjected to antibiotic and mechanical bowel preparation as follows:
 - a- Castor oil 60 ml on the morning of day 1 preparation.
 - b- Oral neomycin 1 g at 1: PM, 2 PM and 11: PM, the day before surgery.
 - c- Oral erythrocine 1g at 1: PM, 2: PM and 11: PM, the day before surgery.
 - d- Repeated enemas.
- 2- Perioperative intravenous antibiotics were given in the form of 300 mg Dalacin-C and 80 mg garamycin.
- 3- Prior to placement of the drape, the stoma was covered with a gauze sponge.
- 4- The previous abdominal incision was reopened.
- 5- Kocher clamps were placed on the fascial edge on the side that contained the stoma to elevate the abdominal wall.
- 6- Adhesions were sharply dissected and any contents of the hernia sac were reduced.

- 7- Two layered polypropylene mesh was designed in the form of pantaloons and the two layers were fixed to each other continuous 0 prolene suture along its perimeter to prevent sliding of one layer over the other. The medial limb was made broader than the lateral limb, usually the lateral limb was made 3 cm wide, to be incorporated in laparotomy closure (Fig. 1).
- 8- The mesh was then placed on either side of the bowel as it existed through the abdominal wall. Using continuous No. 1 prolene suture, we fixed the outer perimeter of the mesh to the inside of the anterior abdominal wall (except at the medial border of the medial limb to allow easy tension of the mesh during repair of the fascial defect).
- 9- Repair of the defect by interrupted sutures (using No. 1 prolene) through one strip of the mesh, through both edges of the fascial defect and through the second strip. The emerging loop was fixed to the mesh by 2 lateral and 2 medial stitches using 3/0 vicryl (Fig. 2).
- 10- Closure of the abdomen incorporating the medial border of the medial limb of the mesh during closure of the laparotomy incision to protect against subsequent incisional hernia.
- 11- The excess skin over the paracolostomy hernia was excised in some cases.
- 12- Postoperative antibiotics in the form of Dalacin-C 300 mg/8 hours and garamycin 80 mg/8 hours were administered for 3 days.

RESULTS

At the stoma care clinic of NCI, 505 patients with left iliac terminal colostomy were seen over the last 5 years. They were 341 males and 164 females. Paracolostomy hernia was detected in 138 out of 505 patients (27.3%), including those who did not require surgical repair. Paracolostomy hernia was more frequent in females (54/164-32.9%) than in males (84/341-24.6%).

Left iliac colostomy construction was performed after radical cystectomy in males or anterior pelvic exenteration in female for bladder carcinoma in (79.2%) of cases (400/505) and after abdominoperineal resection for rectal carcinoma in (20.8%) of cases (105 out of 505 patients).

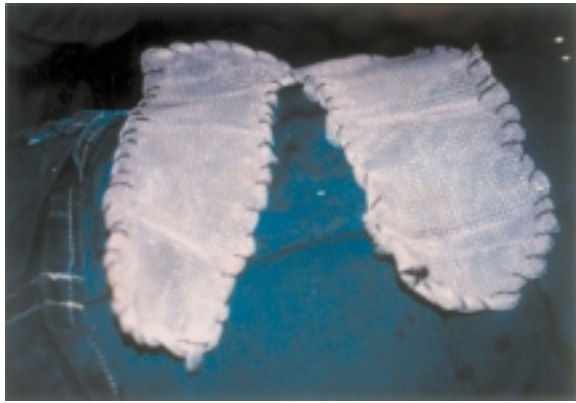


Fig. (1): Double-layered prolene mesh in the form of pantaloons.

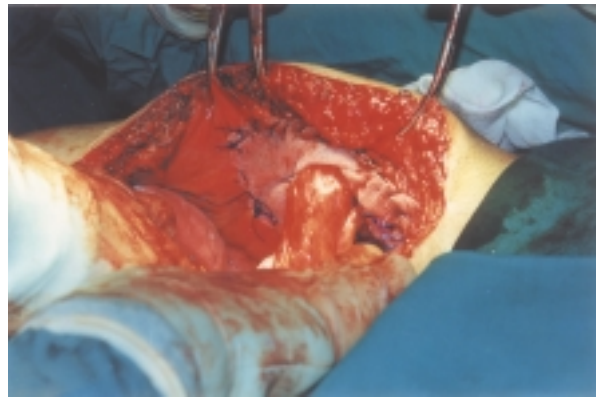


Fig. (2): Trolene-mesh in-situ.

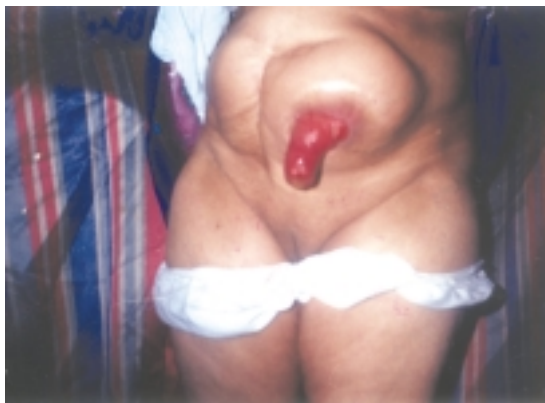

Fig. (3,A): Preoperative.

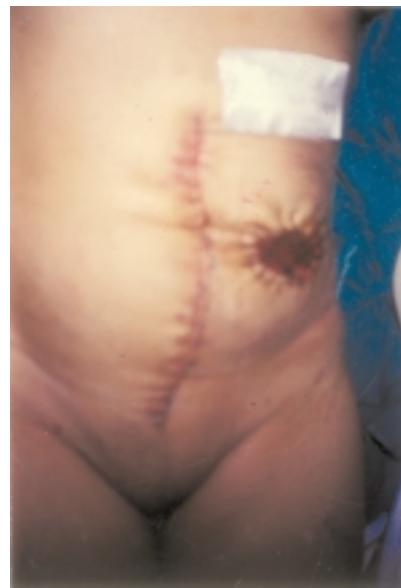

Fig. (3,B): Postoperative.

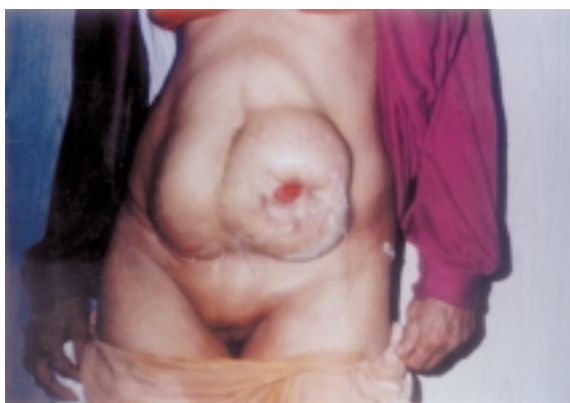

Fig. (4,A): Preoperative.

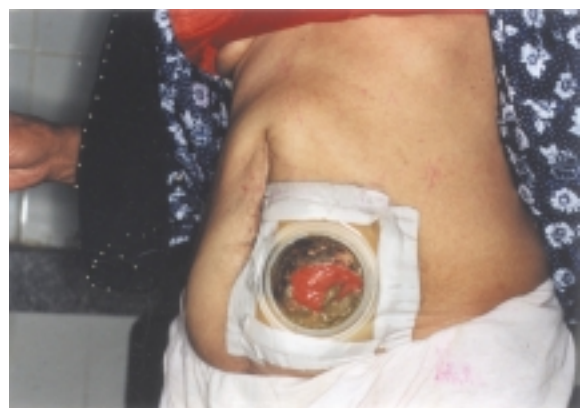

Fig. (4,B): Postoperative.

The mean age at the time of hernia repair was 54 ± 13.6 years. They were 12 females and 8 males. All the hernias started to appear within 2 years after the primary surgery, but there was wide variation in size increase of the hernia over time. Only six patients received postoperative adjuvant systemic chemotherapy, while 4 patients received adjuvant pelvic radiotherapy. Paracolostomy hernia was associated with prolapse of the colostomy in 4 patients. Eight of the females and one male were obese. The mean hospital stay was 10 ± 3 days. The mean amount of blood loss was 200 ± 50 ml. The mean operative time was 90 ± 15 minutes. Mean follow-up was 26 ± 10 months. Successful repair could be achieved in 17 patients and hernia recurrence has been observed in 3 patients during follow up. No other ostomy problems such as prolapse, fistulization, stenosis or retraction have resulted after successful repair during the whole period of follow-up. One patient who had hernia recurrence had also incisional hernia at the upper end of the laparotomy incision. Two patients developed wound sepsis at the laparotomy incision and 2 other patients developed sepsis at the ostomy site after excision of excess skin, but all patients responded to conservative management; none of them warranted mesh removal for wound sepsis. One patient with hernia recurrence was asthmatic and was receiving corticosteroid therapy.

DISCUSSION

Paracolostomy hernia is a frequent late complication of colostomy. However, the prevalence of this complication varies from one series to another. Some authors have reported a frequency of 5% including patients who did not need a reparative operation [20], while others noted a prevalence of about 50% [28]. Others considered this complication to be inevitable, as it occurred in practically all patients studied [9]. This wide variation in the frequency of paracolostomy hernia may be attributed to: (1) Definition of paracolostomy hernia: Some authors include patients with minor degree of parastomal weakness or slight bulge which does not fulfill the criteria for true hernia and seldom requires surgical correction [6,9]. Paracolostomy hernia must be defined as one which appears around the colostomy, either partially or totally surrounding it. (2) Duration of follow-up: Studies in which patients were re-examined 5 or more years following stoma surgery have found a

long-term incidence of paracolostomy hernia of 60% [28]. (3) Inclusion of cases which do not require surgical repair. The prevalence of paracolostomy hernia in this study was 27.3% including hernias which did not need repair.

Ortiz et al. [16] found that prevalence of paracolostomy hernia was more common in males (65.3% versus 34.7% in females) in their study group which involved 54 patients. However, Sjordahl et al. [20] found no significant difference in the prevalence of paracolostomy hernia between males and females (6.2% for males versus 7.7% in females). In the present study paracolostomy hernia was more frequent in females (32.9%) than in males (24.6%). The increased incidence in Egyptian females may be related to weakening of the abdominal wall muscles and fascia due to repeated pregnancies, lack of physical exercises and obesity.

Possible causes of paracolostomy hernia are obesity, increased intra-abdominal pressure from disorders of the respiratory, urinary or gastrointestinal organs or formation of a pocket within the rectus sheath [9]. Obvious predisposition was found in only one patient who had bronchial asthma and was receiving corticosteroid therapy. Like other investigators [2,7], we found that neither increasing age nor the underlying disease influenced the risk of parastomal hernia. Only obesity approached significance as a poor prognostic factor for parastomal hernia, as 45% of our patients were obese. Previous pelvic radiotherapy or chemotherapy may be associated with increased risk of paracolostomy hernia in our patients; as 20% received postoperative adjuvant radiotherapy and 30% have had postoperative systemic chemotherapy.

Technical factors in stoma construction are most commonly believed to be the dominant aetiological factors. Techniques for raising a colostomy which avoid paracolostomy hernia or prolapse have not been described. Goligher [9] described an extraperitoneal technique for construction of terminal left iliac colostomy and mentioned that this could lessen the incidence of parastomal herniation because of the oblique course in which the colon stump then emerges from the abdominal wall, but this has been so. Fixation of the serosa of the bowel to the anterior and posterior rectus sheath in all quadrants was described by Schmidt et al. [19] to prevent parastomal herniation. Although this simple

surgical procedure meets with some success in a minority of patients, success is not always achieved. Helal et al. [11] stated that a large abdominal wall hiatus to prevent bowel ischaemia may facilitate development of parastomal hernia. Therefore they advocate construction of the smallest possible hiatus to possibly prevent this complication. Another proof to the importance of the hiatus size as an aetiological factor for parastomal hernia is the much lower incidence of paraileostomy hernia in different series (5-10%) in comparison to paracolostomy hernia [5]. It has been suggested that the risk of paracolostomy hernia is reduced if the colostomy is sited within the rectus sheath [8]. Sjødhal et al. [20] found the prevalence of parastomal hernia to be 2.8% for transrectus colostomy versus 26.1% for more lateral colostomies; a statistically significant difference. On the other hand, Von Smitten et al. [27] found 48% hernia rate in a review of 54 patients with a terminal colostomy, with no association with the position of the stoma in the abdominal wall. Williams et al. [28] also found no relation between ileostomy position (pararectal or transrectal) and the frequency of paraileostomy hernia. Ortiz et al. [16] found that 26 out of 54 patient with left iliac colostomy to have paracolostomy hernia. Colostomy was pararectal in 15 patients and transrectal in 11 patients, with no statistically significant difference. We cannot substantiate whether a stoma situated in the rectus muscle is better, as all our colostomies were transrectal. Leong et al. [13] found that 14 out of 103 patients who had ileostomy through the rectus muscle had parastomal hernia versus two patients out of 42 with stoma sited through the oblique muscles. They calculated that the cumulative probability of herniation at 20 years was 21% for transrectal ileostomy compared with 7% when sited through the oblique muscle; a statistically significant difference. So, in conclusion from the previous studies it seems that the position of the stoma in the abdominal wall does not influence the rate of paracolostomy hernias. This conclusion may have two practical implications: (1) The preoperative choice of place for the stoma can be carried out in the most comfortable position for the patient without having to be limited to a transrectal position, (2) Surgical repair of paracolostomy hernia does not require a change in the previous position of the stoma.

A number of techniques for the repair of

parastomal hernias have been reported. Goligher [9] recommended relocation of the stoma and primary closure of the fascial defect. Sugerbaker [23] and Byers [4] criticized this approach as it leaves a large fascial defect at the site of the original stoma that must be closed and is at risk for subsequent hernia development. They added that, because of contamination inherent in relocation of the stoma, prosthetic mesh should not be used. Further, factors that led to the development of the parastomal hernia originally are still operative and can lead to subsequent hernia development around the new stoma. Thus, repair of one hernia can ultimately result in two hernias. In a review of stoma problems, Todd [26] states that resiting or relocating a stoma is always a difficult operation and he proposes in situ repair if possible. Rubin et al. [18] also found parastomal hernia recurrence after relocation in 33% of patients and incisional hernias developed in 52%. Also Allen-Mersh and Thomson [2] found good results in only 43% after relocation to the right side of the abdomen while the success rate was only 14% when the stoma was relocated on the left side of the abdomen. After stomal relocation, Kohler [12] observed recurrent parastomal hernias in 40% and incisional hernias in 30% of the patients. Stephenson and Philips [22] added that stoma resiting to the right side of the abdomen is a major operation, particularly if there are extensive adhesions or the splenic flexure needs to be mobilized. They advocate local resiting and tension free mesh herniorrhaphy.

Thorlakson [25] recommends a direct repair via the ostomy site with closure of the defect with non absorbable sutures. Local herniorrhaphy is also described by Block and Giuliano [3] and O'Higgins [15]. Tekkis et al. [24] described a modified Thorlakson technique that incorporated an incomplete circumferential mesh to reinforce the fascial repair. In their preliminary report, 5 cases have been operated on successfully without any serious complication. However, Rubin et al. [18] found parastomal hernia recurrence in 76%, 22 out of 29 patients who had fascial repair. Allen-Mersh and Thomson [2] reported also success rate in only 53% of cases using local repair with non absorbable suture. Stephenson and Philips [22] found local repair to be singularly unsuccessful, with recurrent hernia rates of approximately 50%. They stated that simply repairing a parastomal defect

causes direct stress to the edges of the defect and indirect stress through increased intra-abdominal pressure and both forces may predispose to hernia recurrence. Kohler [12] reported the highest hernia recurrence rate (80%) after local fascial repair and he stated that this method of repair has not longer any indication.

Rosin and Bonardi [17] and Abdu [1] use a sheet of mesh placed over the fascial defect anteriorly, bringing the stoma out through this mesh. Rosin and Bonardi [17] reported excellent results in 7 patients with minimal complications. Abdu [1] published a limited experience with the use of Marlex mesh to repair large paracolostomy hernias in five patients with good results. But Devlin [5] believes that the risk of infection is too high to recommend its use. Leslie [14] reported some adaptation by raising large skin flap utilizing the existing scar and repair the defect subcutaneously using synthetic mesh. Rubin et al. [18] reported 67% success rate after subcutaneous fascial repair with prosthetic mesh. The advantage of subcutaneous placement of mesh is that no laparotomy is required. However, there is a risk of contamination from the stoma. If sepsis occurs, troublesome sinuses follow, which may necessitate subsequent mesh removal.

Sugarbaker and Byers [4,23] advocated transperitoneal prosthetic mesh repair of the fascial defect without the problems that bacterial contamination of the operative field presents. In this method, the stomal bud is not disturbed so that return to normal intestinal function is rapid. Also, the peritoneal approaches offer the advantages of defect closure under direct vision while reinforcing any weak abdominal area.

Sugarbaker [23] described a transperitoneal technique that uses a ring of prosthetic mesh that is fashioned so as it snugly fills the fascial defect. Individual sutures are placed at approximately 1 cm intervals around the fascial ring except directly laterally where the colon will enter the abdominal cavity from the subcutaneous tissue. Colon is secured there with sutures. So, the colon is led out through a mesh flap valve, so that further herniation out around the colon is unlikely. He reported 100% success rate in 7 patients after 4 years follow-up. Stelzner et al. [21] reported on 9 patients with large paracolostomy hernia operated on according to Sugarbaker technique. The hernial orifice was

closed with 30 x 20 cm Gore patch. During follow-up two recurrences were observed.

Byers et al. [4] developed a method of repair that uses 2 strips of polypropylene mesh through a midline incision. Each strip is 3 cm wide, placed on either side of the bowel as it exits through the abdominal wall. Interrupted stitches along the length of the mesh were placed. These stitches were placed through one strip of the mesh, through both edges of the fascial defect and through the second strip of the mesh. Byers et al. [4] reported 100% success rate for 9 patients with no recurrence after 2 years of follow-up. Only one patient developed wound sepsis which responded to external drainage.

In our study, using the described modification of Byers technique, as described above, for repair of large paracolostomy hernia (more than 6 cm in diameter), a 85% success rate was achieved after 3 years follow up. Recurrence of paracolostomy hernia was observed in 3 patients. One of them was obese and developed also small incisional hernia at the upper part of the laparotomy incision. The second patient who developed hernia recurrence was asthmatic and developed severe asthmatic bronchitis post-operatively. In the third patient, wound sepsis is believed to be the aetiological factor. The hernia recurrences were observed during the first year after repair.

Conclusion:

The indications for repair of parastomal hernia are based on a judgement of the degree of inconvenience experienced by the patient balanced against fitness for operation and probability of achieving a successful result. Byers technique avoids the necessity for moving the ostomy and risking the subsequent development of hernia (both incisional and parastomal) after repair of one. It offers the advantages of defect closure under vision while reinforcing any weak abdominal wall area. By isolating the stoma under a gauze sponge and using transperitoneal approach, he kept the dangers of infection of this mesh at a minimum because the operative field is completely uncontaminated. The modification described here seems important in that:

- 1- The two layered mesh gives more strength for the repair.

- 2- Fixation of the mesh perimeter to the inside of the anterior abdominal wall allows easy tension of the mesh during closure of the defect and prevents or decreases the pseudo-bulge at the region due to tissue laxity.
- 3- The broader medial limb of the mesh permits its incorporation in laparotomy closure to prevent or decrease the incisional hernia.
- 4- Fixation of the emerging loop to the mesh prevents possible shearing effect of the mesh on the intestine.
- 5- Removal of excess skin over the hernia with re-establishment of the mucocutaneous junction may be indicated in some cases. It allows better fitting of the appliance and avoids false impression of persistence or recurrence of the hernia.

Further surgical experience with this parastomal hernia repair is indicated; however the favorable initial results suggest that it is indicated especially for hernias with a large fascial defect.

REFERENCES

- 1- Abdu R.A.: Repair of paracolostomy hernia with Marlex mesh. *Dis. Colon. Rectum.*, 25: 529-531, 1982.
- 2- Allen-Mersh T.G. and Thomson J.B.S.: Surgical treatment of colostomy complications. *Br. J. Surg.*, 75: 416-418, 1988.
- 3- Block G.E. and Giuliano A.: Complications of the surgical treatment of ulcerative colitis and Crohn's disease. In: Kirsner J.B. (Ed.). *Inflammatory bowel disease*. 2nd ed. Philadelphia, Pennsylvania: Lea and Febiger, 577-604, 1980.
- 4- Byers J.M., Steinberg J.B. and Postier R.G.: Repair of parastomal hernias using polypropylene mesh. *Arch. Surg.*, 127: 1246-1247, 1992.
- 5- Devlin H.B.: Peristomal hernia. In: Dudley H. (Ed.). *Alimentary tract and abdominal wall*. Rob and Smith's operative surgery. Vol. 1, 4th ed. London: Butterworths, 441-448, 1983.
- 6- Fazio V.: Complications of intestinal stomas. In: Ferrari B., Ray J. and Gathright B. (Eds.). *Complication of colon and rectal surgery*. Philadelphia: WB Saunders, 236, 1985.
- 7- Franchini A., Cola B. and Stevens P.: *Atlas of stomal pathology*. New York: Raven Press, 39: 1983.
- 8- Goldberg S., Gordon P. and Nivatvongs S.: *Essentials of anorectal surgery*. Philadelphia: J.B. Lippincot Company, 198, 1980.
- 9- Goligher J.C.: *Surgery of the anus, Rectum. and Colon*. Baillier Tindall, 5th ed., 439, 1985.
- 10- Grier W.R.N., Postel A.H., Sypars A. and Localio S.A.: An evaluation of the colon stoma management without irrigation. *Surg. Gynecol. Obstet.*, 119: 1234-1242, 1964.
- 11- Helal M., Austin P., Spyropoulos E., Pow-Sang J., Persky L. and Lockhart J.: Evaluation and management of parastomal hernia in association with continent urinary diversion. *J. Urology.*, 157: 1630-1632, 1997.
- 12- Kohler L.: Parastomal hernia-technique and results. *Zentralbl. Chir. (Abst.)*, 122 (10): 889-892, 1997.
- 13- Leong A.P.K., Londono-Schimmer E.E. and Philips R.K.S.: Lofe-table analysis of stomal complications following ileostomy. *Br. j. Surg.*, 81: 727-729, 1994.
- 14- Leslie D.: The parastomal hernia. *Surg. Clin. North Am.*, 64: 407-415, 1984.
- 15- O'Higgins N.: Parastomal hernias. In: Taylor S., Chisholm G.D., O'Higgins N. and Shields R. (Ed.). *Surgical management*. 1st ed. London: Heineman, 828, 1984.
- 16- Ortiz H., Sara M.G., Armendariz P., DeMiguel M., Marti J. and Chocarro C.: Does the frequency of paracolostomy hernias depend on the position of the colostomy in the abdominal wall? *Int. J. Colorectal Dis.*, 9: 65-67, 1994.
- 17- Rosin J.D. and Bonardi R.E.: Paracolostomy hernia repair with Marlex mesh; a new technique. *Dis. Colon. Rectum.*, 20: 299, 1977.
- 18- Rubin M.S., Schoetz D.J. and Matthews J.B.: Parastomal hernia, is stoma relocation superior to fascial repair? *Arch. Surg.*, 129: 413-419, 1994.
- 19- Schmidt J.D., Hawtrey C.E., Flocks R.H. and Culp D.A.: Complications, results and problems of ileal conduit diversions. *J. Urol.*, 109: 210, 1972.
- 20- Sjodahl R., Anderberg B. and Boln T.: Parastomal hernia in relation to site of the abdominal stoma. *Br. J. Surg.*, 75: 339-341, 1988.
- 21- Stelzner S., Hellmich G. and Ludwig K.: Sugarbaker technique in paracolostomy hernia. An analysis of personal experience. *Zentralbl. Chir. (Abst.)*, 124 (2): 13-17, 1999.
- 22- Stephenson M. and Philips R.K.: Parastomal hernia: local resting and mesh repair. *Br. J. Surg.*, 82: 1935-1936, 1995.
- 23- Sugarbaker P.H.: Peritoneal approach to prosthetic mesh repair of paraostomy hernias. *Ann.*

- Surg., 201: 344-346, 1985.
- 24- Tekkis P.P., Kocher M.M. and Payne J.G.: Parastomal hernia repair: modified Thorlakson technique, reinforced by polypropylene mesh. *Dis. Colon. Rectum.*, 42 (11): 1505-1508, 1999.
- 25- Thorlakson R.H.: Technique of repair of herniation associated with colonic stomas. *Surg. Gynecol. Obstet.*, 120: 347-350, 1965.
- 26- Todd I.P.: The resolution of stoma problems. In: Allan R.N., Keighley M.R.B., Alexander-Williams J. and Hawkins C. (Eds.). *Inflammatory Bowel Diseases*. Edinburg: Churchill Livingstone, 256-261, 1983.
- 27- Von Smitten K., Husa A. and Kyllonen L.: Long term results of sigmoidostomy in patients with anorectal malignancy. *Acta. Chir. Scand.*, 152: 211-213, 1986.
- 28- Williams J.G., Etherington R., Hayward M.W.J. and Hughes L.E.: Parastomal hernia: a clinical and radiological study. *Br. J. Surg.*, 77: 1355-1357, 1990.