

## **Modified Inguinal Lymphadenectomy: Short and Long Term Follow Up for Penile Carcinoma**

AMR A. ATTI, M.D.; HASSEN ABDALLA, M.D. and SAMY RAMZY, M.D.

*The Department of Surgical Oncology, National Cancer Institute, Cairo University.*

### **ABSTRACT**

The aim of the study was to determine the staging and therapeutic benefits of a modified inguinal dissection of patients with carcinoma of the penis with either, clinically negative or limited clinically positive inguinal nodes. A modified inguinal lymph node dissection in which the saphenous vein was preserved together with reduction of the lateral, distal and proximal margin of dissection was performed on 10 men who had invasive penile carcinoma and either clinically negative or limited clinically positive inguinal nodes (N<sub>1</sub>). Two out of 7 patients with clinically negative inguinal nodes had histologically positive nodes. Of the 3 patients with clinically involved inguinal nodes, one had histologically negative nodes. One patient with positive node had distant recurrence. The sites of inguinal involvement were localized within the boundaries of the dissection in all patients. No major complications, no permanent lymphoedema nor flap necrosis occurred. None of the patients developed local recurrence in a follow-up period of 4-84 months (median 37 months).

*Conclusion:* The modified inguinal dissection is a reliable staging technique that also provides therapeutic benefit to patients with penile cancer and clinically negative or limited clinically positive inguinal nodes. It can be performed without major troublesome complications.

**Key Words:** *Penile carcinoma - (P.C.) modified - Inguinal lymphadenectomy (M.I.L.).*

### **INTRODUCTION**

The status of regional lymph nodes is the single most important prognostic factor in determining long-term survival in men afflicted with carcinoma of the penis. The fact that patients with negative lymph nodes experience a significant disease-free survival advantage over those with nodal involvement is well known [12,29]. Carcinoma of the penis is associated with clinically palpable inguinal nodes in 35 to 50% of patients at initial presentation but only half of the nodes will be found to contain true metastasis on histological examination. On the

other hand, 20% of men presenting with a negative groin examination have occult metastatic disease, which underlies the inaccuracy of solely relying on clinical evaluation to determine the presence of lymphatic spread to the inguinal nodes [1,14]. The use of computerized tomography, lymphangiography or fine needle aspiration cytology is also fraught with similar constraints, as positive results are only encountered in individuals with clinically suspicious nodes [15]. Controversy exists about whether to perform immediate lymphadenectomy in patients with clinically negative nodes at presentation or to wait until inguinal lymphadenopathy develops during observation [1,28].

Several reports have demonstrated a distinct therapeutic advantage of immediate versus delayed lymph node dissection [7,8,10]. However, standard ilioinguinal lymphadenectomy (Fig. 1) is associated with a 30 to 50% incidence of major complications including debilitating lymphoedema and skin flap necrosis as well as 3% mortality rate [1,13,28]. To identify patients in whom lymphadenectomy is necessary, Cabanas [2] recommended bilateral sentinel lymph node biopsy. The sentinel lymph nodes for carcinoma of the penis are claimed to be located superomedial to the epigastric-saphenous junctions. However, several investigators have reported that the sentinel lymph node biopsies to determine the necessity of lymph node dissection were unreliable [7,9,13,24,30]. Moreover, several patients have been reported in whom incurable lymph node metastases developed after negative bilateral sentinel lymph node biopsy [9,24,30]. Another drawback of biopsy procedures is that postoperative changes may make subsequent clinical examination of the groins

more difficult to interpret. In 1988, Catalona [4] reported a modification of the classical radical groin dissection, in which the lateral and caudal margins of dissection were reduced and the saphenous vein was preserved without the need for transposition of the sartorius muscle.

The goal of the present study was to evaluate: 1) The staging and therapeutic benefits of a modified inguinal lymphadenectomy in men with penile carcinoma who had clinically negative or limited clinically positive nodes. 2) The complications related to the procedure.

### PATIENTS AND METHODS

During the period between March 1993 and February 2001, ten men underwent (MIL) as a regional staging procedure for histologically proven penile squamous cell carcinoma at the National Cancer Institute, Cairo University and outside the institute. The indication for the (MIL) was the presence of invasive squamous cell penile carcinoma (American Joint Cancer Committee Stage PT<sub>1</sub> to T<sub>4</sub>) [27] and a clinically negative or early limited positive inguinal lymph node examination on either or both sides (Figs. 2,3,4). Patients with pathologically proven deep inguinal metastases underwent the traditional ilioinguinal lymphadenectomy on the involved side and modified inguinal dissection on the clinically negative side. Preoperative studies included measurement of liver function tests, kidney function tests, serum electrolytes, chest X-ray, electrocardiogram and computed tomography of the abdomen and pelvis for patients with clinically positive inguinal nodes. After removal of the primary tumor, the patients received broad-spectrum antibiotics for 2 weeks to treat any septic lymphangitis and lymphadenitis caused by primary tumor.

#### *Technique:*

The operation begins with a 10 cm transverse incision approximately 2 cm below the groin crease (Gibson's incision) (Fig. 5-A). The incision is deepened to the level of Scarpa's fascia (Fig. 5-B). The superior flap is then developed in a plane parallel and just deep to Scarpa's fascia (Fig. 5-B). A funiculus of adipose and lymphatic tissue can be identified coursing from the superficial inguinal lymph nodes to the base of the penis. This tissue is ligated and divided. The superior flap is dissected approximately 8 cm superior to the incision

and is deepened to the fascia of the external oblique muscle (Fig. 5-C). The lymphatic tissue deep to Scarpa's fascia is dissected off the external oblique fascia and spermatic cord in a caudal direction to the level of the inguinal ligament (Fig. 5-C). The inferior flap is developed similarly 6 cm below the incision and the incision is deepened to the fascia lata. Saphenous vein tributaries are ligated with fine silk and divided, preserving the main trunk of the saphenous vein and the sapheno-femoral junction (Fig. 5-D). The lymphatic tissue is then dissected off the anterior surface of the saphenofemoral junction. The deep inguinal nodes are dissected out (Fig. 5-E & Fig. 6), they consist of 1 to 3 lymph nodes deep to the fascia lata immediately medial and lateral to the femoral vein (Fig. 5-E). Lymphatic tissue is then dissected off the femoral artery up to the inguinal ligament. This completes the (MIL) (Fig. 2-F). In patients with positive nodes, the limit of dissection may need to be extended superolaterally. The medial margin of the dissection is the adductor longus muscle, the lateral margin is the lateral border of the femoral artery, the superior margin is the external oblique muscle above the spermatic cord and the inferior margin is the fascia lata just distal to the fossa ovalis (Fig. 1). If deep inguinal node metastasis is reported on frozen section, iliac lymphadenectomy is performed. The wound is closed and closed suction drainage is maintained until drainage is less than 50 ml/day. Likewise, sequential compression stocking is used until the patient is fully ambulatory. The use of elastic stockings is recommended for at least 6 to 8 weeks postoperatively to minimize the likelihood of lymphoedema. A 300 mg aspirin is given daily indefinitely as a prophylactic measure for deep vein thrombosis.

Postoperative adjuvant chemotherapy with 5 courses of methotrexate, bleomycin and cisplatin was administered to one patient with T<sub>3</sub>N<sub>2</sub>M<sub>0</sub> disease. None of the patients received adjuvant radiotherapy. Eight patients were followed up every 4 months during the first year, while 2 patients were examined infrequently. Subsequently, after the first year of follow-up, visits were variable (after year 1). The median follow-up was 37 months (range 4-84 months). Follow-up studies consisted of physical examination as well as computerized tomography when appropriate.

## RESULTS

The clinicopathological characteristics of all patients are presented in Table (1). The median age was 58 years (range 49-74 years). Seven patients had clinically normal nodes while two had a small shotty inguinal nodes. One patient had unilateral clinically positive nodes and contralateral small shotty nodes that were not suspicious for cancer and disappeared after antibiotic therapy. Of the ten patients, four had histologically involved lymph nodes and in 3 of them the primary penile lesion was T<sub>3</sub> squamous carcinoma (Table 1). In all four patients with positive nodes the supermodial group was involved. In one patient, there was a unilateral spread to the deep inguinal nodes, however, the iliac nodes were not involved. Two patients had a bilateral superficial inguinal involvement. the fourth patient had a unilateral superficial positive nodes.

Early postoperative complications occurred in three patients with small area (< 1 cm) of skin-flap necrosis, which healed secondarily without complication, in three patients with prolonged lymphatic drainage (23,28,30 days) and in two with cellulitis requiring repeated percutaneous aspiration and antibiotic therapy.

Three patients suffered transient mild lower extremity oedema after resuming normal activity, but non of the patients had troublesome or debilitating lymphoedema that altered their normal lifestyle except the left lower limb of the patients who underwent the traditional ilioinguinal block dissection for N<sub>2</sub> nodes. Four patients still required elastic stocking support for lymphoedema. One patient died of metastatic disease after 57 months, while two patients lost follow-up after 37, 56 months. All other seven patients are currently alive with no evidence of recurrent disease.

Table (1): Clinicopathological characteristics.

Pt. No.	Parnological stage of the primary tumor	Extent of penile stage	Clinical inguinal node stage	Parnologic finding of the inguinal nodes	Extent lymphadenectomy	Postoperative complications	Current states	Follow-up (months)
1	T <sub>2</sub>	Partial	N <sub>0</sub>	Bilateral negatlive	Modified	- Mild left ankle edema - 1x2 mm wound edge slongh	NED	62
2	T <sub>2</sub>	Partial	N <sub>0</sub>	Bilateral negative	Modified	Prolonged lymphorrhea (28 days)	NED	34
3	T <sub>3</sub>	Partial	N <sub>0</sub>	Bilateral positive (SEL)	Modified	- Moderate penile oedema - Cellulitis of the inguinal incision	NED	4
4	T <sub>1</sub>	Partial	N <sub>0</sub>	Bilateral negative	Modified	- Penile oedema - Prolonged lymphorrhea (30 days)	Lost follow-up at August 1997	37
5	T <sub>3</sub>	Total	N <sub>1</sub>	Bilateral positive (SEL)	Modified	Calf and thigh oedema (transient)	NED	13
6	T <sub>3</sub>	Total	N <sub>2</sub>	-Rt -ve -Lt +ve	Rt. Modified Lt. Ilioinguinal	- 2x4 wound edge slough - Cellulitis - Massive (Lt.) lower limb oedema	Died Lung & bone metastases	57
7	T <sub>2</sub>	Partial	N <sub>1</sub>	Bilateral negaitve	Modified	3x4 mm wound edge slough	last follow-up at May 1999	46
8	T <sub>2</sub>	Partial	N <sub>0</sub>	Bilateral negative	Modified	- Rt. thigh and calf oedema - Penile oedema	NED	7.3
9	T <sub>1</sub>	Partial	N <sub>0</sub>	Bilateral negative	Modified	No complications	NED	84
10	T <sub>2</sub>	Partial	N <sub>0</sub>	Unilateral positive (SEL)	Modified	- Prolonged lymphatic drainage (23 days) - Penile oedema	NED	24

SEL: Superficial inguinal lymph nodes.

NED: No evidence of disease.

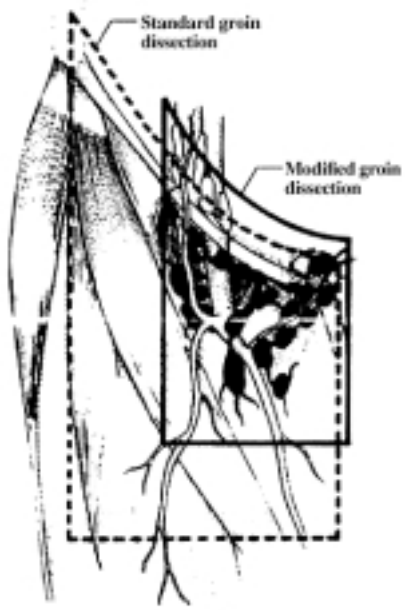


Fig. (1): Limits of dissection of (MIL) and standard groin dissection (after Catalona [3 or 4]).

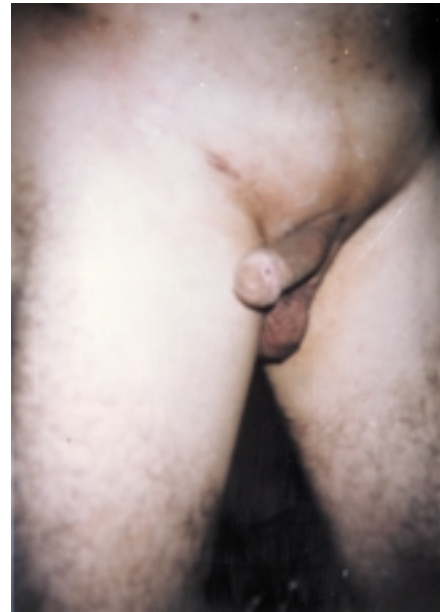


Fig. (2): Example of T1 penile cancer.



Fig. (3): Example of T1 penile cancer.

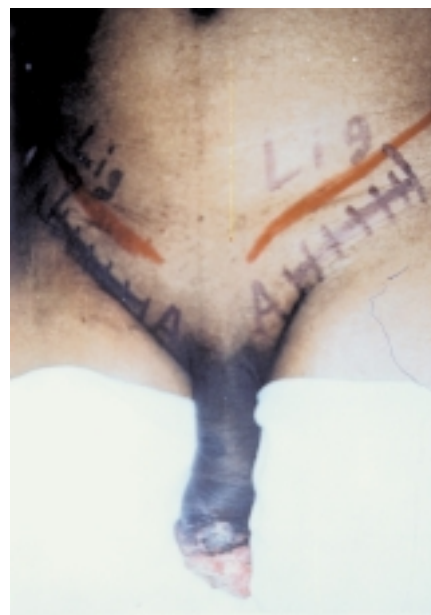

Fig. (4): Showing A: T2 primary penile lesion. B: Gibson groin incision.

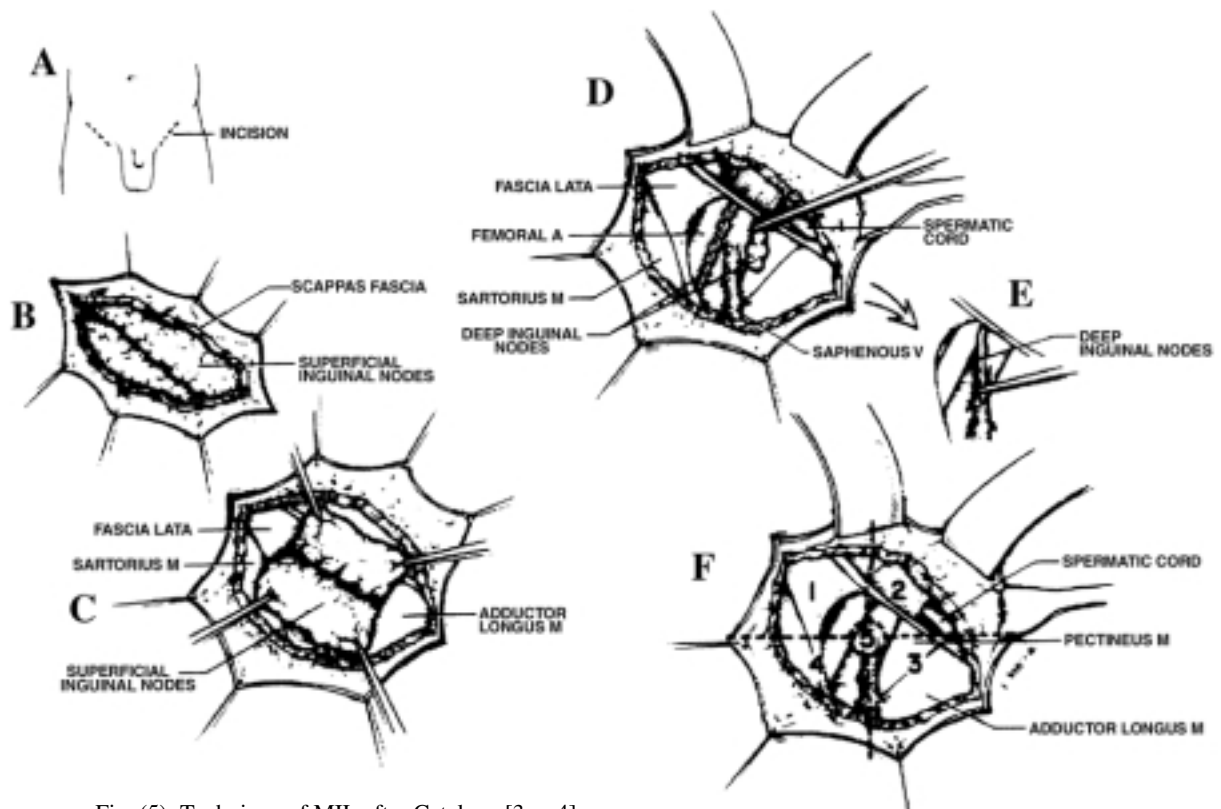


Fig. (5): Technique of MIL after Catalona [3 or 4].

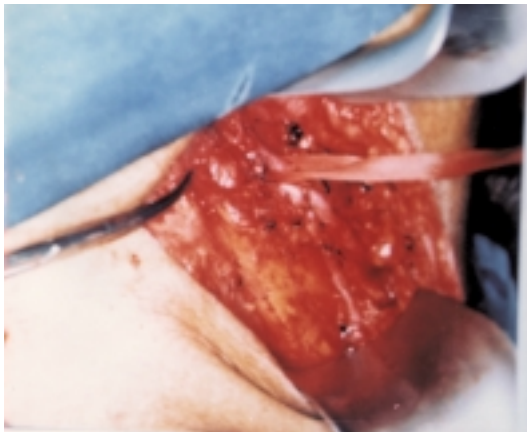


Fig. (6): Operative field showing preservation of the saphenous and sapheno-femoral junction, femoral artery and superficial and deep inguinal lymph node are dissected out.

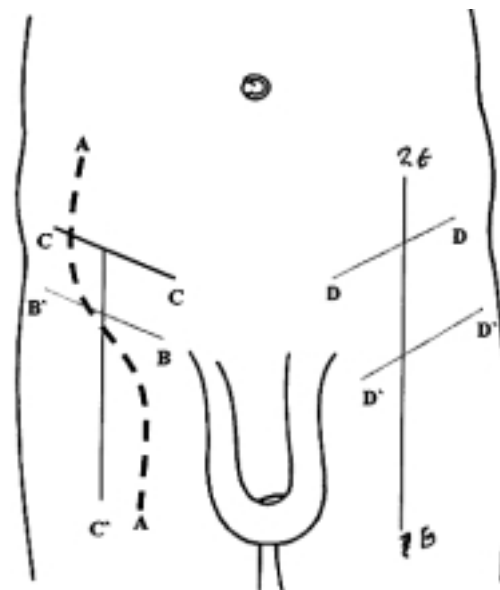


Fig. (7): Incisions used for groin dissection. A-A S-shaped incision, B-B horizontal (groin crease) incision. C-C-C' T-shaped incision D-D and D'-D' two parallel horizontal incisions (skin bridge technique), E-E vertical incision.

### DISCUSSION

Lymph node dissection is the most effective way to eradicate small metastatic deposits in patients with invasive carcinoma of the penis [27]. The lack of effective adjunctive radiothera-

py and chemotherapy and equal lack of adequate noninvasive staging modalities to assess the pelvic and inguinal nodes lend further support to the performance of inguinal lymph node dissection [3,10,15]. Therefore, it is argued that patients should undergo surgery at the earliest

possible time, preferably before node invasion is clinically detected. However, the considerable postoperative complications associated with standard groin dissection as described by Daseler et al. [6], pose a serious drawback when propagating the use of lymph node dissection in all patients who present with penile carcinoma, stressing the need to avoid unnecessary node dissection [16]. Areas of controversy are the management of patients with clinically negative nodes and the extent of node dissection. Several studies strongly support immediate lymph node dissection. Johnson and Lo [18] reported 5 year survival rate of 57% for prophylactic groin dissection versus 13% for the therapeutic dissection. McDougal et al. [20] in their series of 46 patients with invasive disease reported a 5-year disease-free survival of 88% for those with stage II and 66% for those with stage III disease who underwent immediate lymphadenectomy versus a dismal 38 and 0%, respectively, for men who were treated expectantly with or without groin dissection.

Another important argument against delayed lymphadenectomy is that not uncommonly patients with penile cancer, once the primary lesion is removed, are unable to or neglect follow up. This together with the propensity of penile cancer to advance and metastasize rapidly can lead to failure in diagnosing groin metastasis early enough to perform salvage lymphadenectomy.

Irrespective of the clear staging and therapeutic benefits that inguinal lymphadenectomy offers, there is no question that the considerable morbidity associated with the classical lymphadenectomy as described by Daseler et al. [6] may represent over treatment for patients with a clinically negative groin. The considerable extent of this dissection can cause devascularization of the skin flaps and interruption of the lymph channels that directly contribute to the development of flap necrosis and lymphoedema [23].

The fact that several different types of incisions have been proposed to approach the inguinal nodes is germane to the difficulties associated with radical ilioinguinal lymphadenectomy (Fig. 7). Ornellas et al. [22], reviewed 3 approaches in 112 patients undergoing a total of 200 consecutive lymphadenectomies. In 21 patients who received a bi-iliac incision the incidence of flap necrosis and lymphoedema was

82% and 9%, respectively. In 47 men in whom an "S" shaped incision was used, flap necrosis developed in 72% and lymphoedema occurred in 32%. In the remaining 44 patients in whom a Gibson incision was adopted the incidence of flap necrosis was reduced to 5%. However, wound infection and lymphoedema still occurred in 15% and 16% of the patients, respectively. In the current study, there was no major flap loss but only from 1 to 4 mm skin edge necrosis occurred in 3 patients (30%), all healed spontaneously after repeated dressings. Wound infection occurred in 2 patients (20%) and seroma formation in 3 other patients (30%). Mild to moderate transient lymphoedema was found in 3 patients (30%), but it resolved completely.

Based on the anatomical lymphatic studies by Rouviere [26], Cabanas [2] recommended bilateral biopsy of the superomedial superficial group of the inguinal nodes as a means of identifying those patients with lymph node involvement who are more likely to benefit from complete lymphadenectomy than those with negative nodes. Based on these studies, he demonstrated the existence of specific lymph node center, the so-called sentinel lymph nodes, which are claimed to be located at the junction of the epigastric and saphenous veins. However, subsequent reports have noted the inaccuracy of this method, with unresectable lymph node metastasis developing in several patients in whom initial sentinel biopsies were obtained [7,9,13,24]. Attempts to modify the procedure to an extended sentinel node biopsy, consisting of dissection of all lymph node tissue medial to the saphenous femoral venous junction between the superficial epigastric vein and inguinal ligament, were equally discouraging. Pettaway et al. [25] reported a substantial false-negative rate of 25% in 20 patients.

The (MIL) as described by Catalona [4] is based on the pattern of lymphatic drainage of the penis which has been precisely described by Rouviere [26]. By surgically removing the lymphatics from the superomedial, inferomedial central and deep areas, the primary sites for nodal metastasis in carcinoma of the penis are effectively excised. In the original series of Catalona [4] and the recent update by Colberg et al. [5], all positive nodes were found in the upper medial quadrant of the groin. There had been no local recurrences in the groin, even though the lateral and inferior nodes were not resected.

Non of their patients with negative nodes had evidence of tumor recurrence. All their nine patients were alive with no evidence of disease. Early postoperative complications occurred in most of their patients, but they resolved completely including lymphoedema. Parra [23] also performed modified inguinal dissection on 12 men with invasive squamous carcinoma of the penis and negative inguinal nodes. Five patients identified with nodal metastasis and the sites of inguinal nodes were localized within the boundaries of the dissection in all patients. With a follow-up of 14 to 72 months, no major complications occurred and no permanent lymphoedema or flap necrosis was encountered. Non of their patient had recurrent disease. In the present study all 7 patients with clinically negative nodes were diagnosed and accurately staged; two of them were identified with lymph node metastasis and the superomedial nodes were involved, findings that paralleled those of Catalona [4]. One patient out of the seven who had clinically negative nodes was found to have bilateral groin disease. Although, the median follow-up was short (37 months), non of the patients experienced recurrent disease except for the case with deep inguinal metastasis at the time of presentation. These findings compare favorably with the series using more extensive dissection and suggest that the modified dissection also has a therapeutic role in cases with early limited nodal involvement. Early postoperative complications occurred in most of our patients, but they resolved completely including lymphoedema. Because the lymphatic channels lateral to the femoral artery were not removed and great saphenous vein was preserved, the incidence and severity of lower extremity oedema was reduced. Coupled with the use of a shorter incision with thick skin flaps, in which the subcutaneous tissue above Scarpa's fascia was maintained, major skin-flap necrosis was virtually eliminated.

The dynamic sentinel node procedure is minimally invasive and seems promising to identify patients with clinically occult metastasis at an early stage disease who require lymph node dissection. This technique has been used successfully to identify the sentinel node in patients with malignant melanoma and is now being explored for other types of malignancies such as breast cancer and carcinoma of the vulva [13,19]. However, the role of intraoperative lymphatic mapping in patients with penile can-

cer awaits further study.

In conclusion, the modified groin dissection as described by Catalona [4] is a safe and effective means of identifying men with penile cancer and clinically negative inguinal nodes and a reasonable alternative to surveillance. The procedure provides staging information similar to the standard inguinal lymphadenectomy. Larger number of patients and longer follow up are required to give a definite conclusion. Until the results of the dynamic sentinel node procedure are available, modified inguinal lymphadenectomy in patients with carcinoma of the penis with either clinically negative or early limited positive nodes should be the diagnostic and the therapeutic procedure of choice.

## REFERENCES

- 1- Beggs J.H. and Spratt J.S.Jr.: Epidermoid carcinoma of the penis. *J. Urol.*, 91: 166-175, 1964.
- 2- Canabas R.M.: Approach for the treatment of penile carcinoma. *Cancer*, 39: 456-466, 1977.
- 3- Catalona W.J.: role of lymphadenectomy in carcinoma of the penis. *Urol. Clin. N. Amer.*, 785-794, 1980.
- 4- Catalona W.J.: Modified inguinal lymphadenectomy for carcinoma of the penis with preservation of the saphenous veins: Techniques and preliminary results. *J. Urol.*, 140: 306-310, 1988.
- 5- Collberg W.J., Andriole G.L. and Catalona J.W.: Long-term follow-up of men undergoing modified inguinal lymphadenectomy for carcinoma of the penis. *Br. J. Urol.*, 79: 54-57, 1997.
- 6- Daseler E.H., Anson B.H. and Reimann A.F.: Radical excision of inguinal and iliac lymph glands: a study based upon 450 anatomical dissection and upon supportive clinical observations. *Surg. Gynecol. & Obst.*, 87: 679-694, 1948.
- 7- DeKernion J.B., Tynberg P., Persky L. and Fegen J.P.: Carcinoma of the penis. *Cancer*, 32: 1256-1262, 1973.
- 8- Fegen P. and Persky L.: Squamous cell carcinoma of the penis: its treatment, with special reference to radical node dissection. *Arch. Surg.*, 99: 117-125, 1969.
- 9- Fowler J.E. Jr.: Sentinel lymph node biopsy for staging penile cancer. *Urology*, 23: 352-358, 1984.
- 10- Fraley E.E., Zhang G., Sazama R. and Lange P.H.: Cancer of the penis. Prognosis and treat-

- ment plans. *Cancer*, 55: 1618-1626, 1985.
- 11- Giuliano A.E., Kirgan D.M. and Guenther J.M.: Lymphatic mapping and sentinel lymphadenectomy for breast cancer. *Ann. Surg.*, 220: 391-395, 1994.
  - 12- Grabstald H.: Controversies concerning lymph node dissection for cancer of the penis. *Urol. Clin. N. Amer.*, 7: 793-802, 1980.
  - 13- Gursel E.O., Gergountzosz C., Uson A.C., Melicow M.M. and Veenema R.S.: Penile cancer: clinicopathologic study of 64 cases. *Urology*, 1: 569-574, 1973.
  - 14- Hardner G.J., Bhanalph T., Murphy G.P., Albertr D.J. and Moore R.H.: Carcinoma of the penis: analysis of the therapy in 100 consecutive cases. *J. Urol.*, 108: 428-440, 1972.
  - 15- Horenblas S., Van Tinteren H., Delemarre J.E.M., Lustig V. and Kroger R.: Squamous cell carcinoma of the penis: accuracy of tumor nodes and metastasis classification system and role of lymphangiography, computerized tomography, scan and fine needle aspiration cytology. *J. Urol.*, 146: 1279-1281, 1991.
  - 16- Horenblas S., Vantinteren H., Delemarre J.F.M., Moonen L.M.F., Lustig V. and Waardenburgh E.W.: Squamous cell carcinoma of the penis III. Treatment of regional lymph nodes. *J. Urol.*, 149: 492-497, 1993.
  - 17- Horenblas S., Jansen L., Meinhardt W., Hoefnagel C.A., Jong D. and Nieweg O.E.: Defection of occult metastasis in squamous cell carcinoma of the penis using a dynamic sentinel node procedure. *J. Urol.*, 163: 100-104, 2000.
  - 18- Johnson D.E. and Lo R.K.: Management of regional lymph nodes in penile carcinoma. Five-year results following therapeutic groin dissection. *Urology*, 24: 308-315, 1984.
  - 19- Levenback C., Burke T.W. and Morris M.: Potential applications of intraoperative lymphatic mapping in vulvar cancer. *Gynecol. Oncol.*, 59: 216-220, 1995.
  - 20- McDougal S.W., Kirchner F.K.Jr., Edwards R.H. and Killion L.T.: Treatment of carcinoma of the penis: the case for primary lymphadenectomy. *J. Urol.*, 136: 38-41, 1986.
  - 21- Morton D.L., Wen D.R. and Wong J.H.: Technical details of intraoperative lymphatic mapping for early stage melanoma. *Arch. Surg.*, 127: 392-397, 1992.
  - 22- Ornellas A.A., Correa, Seixas A.L. and DeMoraes J.R.: Analysis of 200 lymphadenectomy in patients with penile carcinoma. *J. Urol.*, 146: 330-336, 1991.
  - 23- Parra R.O.: Accurate staging of carcinoma of the penis in men with nonpalpable inguinal lymph nodes by modified inguinal lymphadenectomy. *J. Urol.*, 155: 560-563, 1996.
  - 24- Perinetti E.P., Ccrane D.B. and Catalona W.J.: Unreliability of sentinel lymph node biopsy for staging penile carcinoma. *J. Urol.*, 124: 734-740, 1980.
  - 25- Pettaway C.A., Pister L.L. and Dinney C.P.N.: Sentinel lymph node dissection for penile carcinoma: the M.D. Anderson Cancer Center Experience. *J. Urol.*, 154: 1999-2003, 1995.
  - 26- Ronviere H.: Anatomy of the human lymphatic system. Translated by M.J. Tobias. *Ann. Arbor, Michigan: Edwards Brothers*, p. 218, 1938.
  - 27- Schellhammer P.F., Hordan G.H. and Schlossberg S.M.: Tumors of the penis. In: *Campbell's Urology*, 6th ed., Edited by P.C. Walsj A.B., Retik T.A., Stamey and E.D. Vaughan, Jr. Philadelphia: W.B. Saunders Co., Vol. 2 Chapt. 31, pp. 1264-1298, 1992.
  - 28- Skinner D.G., Leadbetter W.F. and Kelly S.B.: The surgical management of squamous cell carcinoma of the penis. *J. Urol.*, 107: 273-279, 1972.
  - 29- Srinivas V., Morse M.J., Herr H.W., Sogani P.C. and Whitmore W.F. Jr.: Penile cancer: relation of extent of nodal metastasis to survival. *J. Urol.*, 137: 880-891, 1987.
  - 30- Wespes E., Simon J. and Schulman C.C.: Cabanas approach: is sentinel node biopsy reliable for staging penile carcinoma? *Urology*, 28: 278-284, 1986.