

## Radiobiology of Bladder Urothelium Clinical Significance: An Overview

HASSAN K. AWWAD

*The Department of Radiotherapy, National Cancer Institute, University of Cairo.*

### ABSTRACT

Despite the fact that the bladder urothelium has a slow turnover rate, it can express a transient acute effect presenting as reduced bladder storage capacity. This is thought to be due to radiation-induced functional and biochemical changes leading to increased bladder tone and is unrelated to cell proliferation. Late radiation effect can be either (1) a consequential damage resulting from the biochemical intracellular changes of early damage, (b) primary late damage resulting from a late expression of urothelial cell death or stromal and vascular changes resulting from liberation of growth factors, principally the TGF- $\beta$ . For early effects the  $\alpha/\beta$  ratio is estimated to be range from 11-12 Gy as in a typical early reacting tissue while for late reactions an estimate of 5-6 Gy has been made suggesting less sensitivity to variations in the fraction size than most late reacting tissues. Local instillation of formalin and hyperbaric oxygen provide useful therapeutic measures for late radiation bladder reactions.

**Key Words:** *Bladder urothelium - Radiation cystitis - Haemorrhagic cystitis - Radiobiology.*

#### 1- Functional and structural organisation of the urothelium:

The urothelium consists of a basal layer, one or more intermediate layer(s) and a superficial layer. Desmosomes connect urothelial cells of all layers while tight junctions connect adjacent cells of the superficial layer. In the swine bladder and probably also in man, surface cells are also covered by a layer of mucus that protects it against bacteria [30]. The stem cells are located amongst the cells of the basal cell layer. Under normal circumstances, very little proliferative activity occurs in the basal cell layer indicating a slow cell turnover rate [2]. The most superficial layer is composed of very large specialized cells ("umbrella cells") each stretching to cover up to 20 cells of the underlying intermediate cell layer. The apical surface of the urothelium plasma membrane is covered by numerous rigid-looking

plaques made up of an outer thick leaflet connected to a much thinner inner lipid bilayer (Fig.1) [29,44,45,46,49]. The thick outer leaflet plaques are composed of protein particles that form crystalline hexagonal arrays separated by thinner "hinge" zones. The hinge which interconnects the urothelial plaques is made up of a 85-100 kDa glycoprotein (UGP85) [48]. The plaques themselves contain four major integrated proteins called uroplakins (UP). A uroplakin molecule has extracellular (luminal), transmembrane and cytoplasmic domains. The bulk of most uroplakin molecules projects into the luminal space where they interact tightly with each other to form the membrane protein particles. The transmembrane domain penetrates through the lipid bilayer to anchor the uroplakin molecule to the cytoplasm via the short cytoplasmic domain (Fig. 1). The urothelial membrane serves certain functions:

1- The plaques along with their hinges a structural strength and malleability to the urothelium and increase its durability despite repeated stretch and bending. Urothelial plaques have been suggested to be dynamic structures that can rearrange themselves by breaking down and fusing up again to give rise to new plaques with new intervening hinges [27,29].

2- The permeability of the surface epithelium is limited by the tight junctions between neighbouring cells, the surface plaques with their crystalline structure and the lipid composition of the deep leaflet of the plasma membrane [6]. Permeability is also limited by the tight contact between the urothelial cells and the extracellular matrix (ECM) [26]. Permeability may increase as a result of cystitis, radiation and the action of

certain drugs such as cyclophosphamide. These may act through destruction of the tight junctions or breaking the continuity of the surface cells. Lack of tight junctions between tumour cells (particularly poorly differentiated bladder cancer) may also increase the permeability of the bladder mucosa. This permits the topical intravesical application of therapeutic agents for treating superficial tumours.

3- The structure of the surface cells helps the bladder mucosa to accommodate itself to the state of bladder filling. During bladder contraction the parts of the surface membrane lying between the hinges bulge inwards to form vesicle-like structures that retract back again when the bladder is distended [27,48].

As mentioned before UPs represent the major differentiation products of normal urothelial cells. The genes of a number of uroplakins have been recently isolated. Expression of UP is maintained by a large proportion of urothelial tumours; > 80% of noninvasive papillary transitional cell carcinomas (TCCs), > 50% of invasive TCC and > 60% of metastases but none of the nonurothelial tumours [45]. The transitional cell urothelium can undergo metaplasia into a squamous cell epithelium under the influence of chronic infection (notably schistosomiasis) or vitamin A deficiency [19,22,36]. These conditions predispose to occurrence of squamous cell carcinoma (SCC). Bladder cancer associated with schistosomiasis can be of the TCC but is more often a squamous cell cancer (SCC). A recent study showed expression of UP in 40% of classical TCC, 13% in TCC cancer associated with schistosomiasis and in only 3% in SCC associated with schistosomiasis. Less often, bladder cancer can be an adenocarcinoma. It seems therefore that, in man, the bladder urothelium can pursue three differentiation pathways: the urothelial type that expresses the UP proteins, epidermal type expressing K1 and K10 keratinization markers and the glandular type. Vitamin A deficiency is known to transform the bladder urothelium into a densely keratinized epithelium which closely resembles the dense keratinization seen in the skin keratinocytes. In contrast, keratinization induced by vitamin A deficiency in the rabbit corneal, conjunctival and oesophageal epithelia is much less dense with less accumulation of keratins K1 and K10. It has also been suggested that vitamin A deficiency can play a

role in the genesis of squamous cell bladder cancer. The postnatal rat bladder epithelium when combined with embryonic urogenital sinus mesenchyme can develop into a prostatic epithelium. This possibility may account for the observation that a few cases of locally advanced and metastatic bladder TCC express prostate-specific antigen (PSA) [7]. Colonic epithelial metaplasia may also occur in the bladder epithelium [5]. It seems therefore that the stem cells in the basal cell layer of the bladder urothelium can undergo three differentiation pathways according to the prevailing environmental signals. Alternatively the three different cell types may have different cell origins.

#### 2- The UB can express early and late radiation reactions:

The UB can express a transient early (acute) and a late radiation response [1,12,33]. Clinically the acute response is observed 4-6 weeks from the beginning of a conventional fractionated radiotherapy and lasts for a few weeks after which the reaction completely subsides. Late effects are expressed after a latent period of several months up to years. In contrast to acute radiation cystitis the late response is irreversible and progressive [33]. Clinically the symptoms in both phases are similar and are mainly frequency, dysuria and urgency. These are manifestations of impairment of the bladder storage capacity though the underlying mechanisms in the acute and chronic response phases are different.

The bladder reservoir function has been experimentally used in the mouse model to study radiation or drug-induced bladder damage [33]. One useful practical endpoint is the 50% decrease in the estimated bladder volume at a certain intravesical pressure (10 or 20 mm Hg) in relation to the pretreatment control value in the same animal. Fig. (3) illustrates that the reduced bladder compliance noted during the acute phase 14 days after irradiation is reversible and compliance is restored back to normal 35 d after irradiation. The bottom curve obtained 160 days after irradiation illustrates the final irreversible loss of compliance reflecting the marked diminution of bladder capacity in the late phase of radiation-induced damage. It can be seen that these experimental patterns reproduce well the development and progression of acute and chronic radiation cystitis in patients subjected to pelvic irradiation.

A more recent study [12] on a mouse model showed that the acute bladder response to a single radiation dose was biphasic with two distinct waves from day 1-15 and day 16-30 followed by recovery which lasted until late cystitis was expressed. As discussed below the two acute phases have been suggested to have different biological backgrounds.

### *2.1- Reduction in bladder storage capacity in acute radiation cystitis caused by functional biochemical changes unrelated to proliferation:*

According to classical radiobiology principles, the healthy UB mucosa is not expected to express early radiation reactions in view of its slow cellular turnover rate. In the mouse model, the reduction in the bladder storage capacity is the main manifestation of acute radiation-cystitis. This has been shown not to be associated with notable changes in the architecture or cell density in any of the three cell layers of the bladder mucosa [12,14,15,16]. This is contrary to what is expected in an early reacting tissue such as the skin or intestinal mucosa. More recent studies in animal models could correlate changes in the bladder storage capacity in the acute phase of radiation cystitis with functional biochemical changes unrelated to cell proliferation. The tone of the bladder muscle is regulated by prostaglandins (PGs) produced by the urothelium as well as by endothelial cells [14]. Post-radiation increase in PG formation by these cells might increase the bladder tone and reduce its storage capacity. In the mouse model this possibility is consistent with the demonstration that intravesical or oral administration of acetyl salicylic acid (a nonsteroidal anti-inflammatory agent) could induce a significant increase in the bladder capacity during the acute phase of radiation cystitis [14]. This effect could be demonstrated only during the first of the two waves of acute cystitis suggesting that prostaglandins are involved in the initial phase of early radiation-induced damage [12].

In an early reacting tissue, an inflammatory response can be demonstrated in which E-selectin and the intracellular adhesion molecule-1 (ICAM-1) play a role through initiation of neutrophil adhesion to endothelial cells and extravasation of leukocytes into the injured tissue [23]. Increased expression of ICAM-1 could be demonstrated in the urothelium during the acute

phase of radiation cystitis in the mouse model. However, this increase did not correlate with the acute functional response [26]. It has also been proposed that damage of urothelial cells might be induced by leakage of urine constituents due to impairment of the urothelial barrier function. Immunohistochemical studies could demonstrate characteristic changes in the urothelial structural protein expression that may correlate with changes in bladder storage capacity. These include Uroplakin III, (a component of the superficial structural protein layer), cytokeratin 18 (a differentiation marker), CD44 and syndecan (cell-cell contact and communication molecules) [16,17]. Changes in these structural proteins were predominantly seen between 2-4 weeks after a single radiation dose. This coincides with the second wave of the two components of acute cystitis. Uroplakin III was shown to be significantly reduced in the basal cell layer during the acute phase of radiation cystitis and this seemed to correlate with reduction in the functional bladder capacity. In contrast, an elevated level of CK18 protein in the superficial umbrella cells was associated with restoration of bladder storage function. Other changes noted during the acute phase with reduced bladder storage capacity include an increased expression of cell/cell communication molecules: CD44 in the intermediate cell layer and syndecan in the superficial cell layer. Proteoglycans molecules which, are main regulators of the permeability of the extracellular matrix may also be implicated in the acute phase [14].

### *2.2- Response to cyclophosphamide, ifosfamide and temozolomide:*

Haemorrhagic cystitis is a main complication of the two cytotoxic agents cyclophosphamide (CY) and ifosfamide. Acrolein, the main metabolic product of both agents, is excreted in urine where it can induce direct damage of the surface urothelium [8]. Normal cells are able to break down acrolein and to reduce its effect. Glutathione can confer protection against acrolein but its concentration in urine is low [41]. Bladder toxicity is expressed within a few days as epithelial denudation, ulceration and haemorrhage. This is soon followed by a regenerative response in the basal cell layer, which spreads, to the intermediary layers. Recovery of the urothelium may occur within a few weeks. However, epithelial abnormalities and increased proliferation may persist for a number of months. An interac-

tion between CY-induced and radiation-induced bladder damage is a problem to be considered when such a combination is used. This problem is discussed below. Temozolomide is a relatively new alkylating agent that has been tested for treatment of metastatic brain tumours arising from primary breast cancer as well as for malignant glioma. Haemorrhagic cystitis has been recently reported in a patient during the second week of administration of this drug [25].

Mesna is a free radical scavenger sulphhydryl compound that can prevent haemorrhagic cystitis induced by CY or ifosphamide [40]. After IV injection, mesna undergoes rapid oxidation to form mesna disulfide which forms a complex with the terminal methyl group of acrolein to form a nontoxic thioether. Its presence in urine blocks spontaneous degradation of CY to acrolein. Since mesna is hydrophilic it does not penetrate cells and does not therefore interfere with the drug antitumour effect.

In a rat model amifostine (WR2721) has been shown to protect against cyclophosphamide-induced cystitis when administered prior to cyclophosphamide administration [43]. This possibility has still to be tested in man.

2.3- Late radiation cystitis: clinicopathological manifestations and pathogenesis:

Manifestations of chronic radiation cystitis are expressed after a dose-dependent latency as frequency, dysuria (reflecting reduced bladder capacity) and haematuria. These symptoms correspond to irreversible pathological lesions involving both the urothelium and the stroma in the submucosa and bladder wall [42]. Urothelial damage can lead to denudation and ulceration. This is followed by the appearance of regenerative changes within the denuded epithelial surface. The regenerative process may produce a "pseudocarcinomatous" proliferative vascular lesion with transitional or squamous cell proliferation [4]. Healing of the urothelium may be complete but completely denuded epithelial surface can only heal by scar formation. A chronic necrotic ulcer may persist and end in fistula formation. Fibrosis of the bladder wall with bladder contraction and reduced capacity is a major feature of late bladder damage. Endothelial cell damage with a slow development of telangiectasis can slowly take place as a consequence of regeneration of damaged endothelial cells. Telangiectasis tends to develop slowly and may

take years before the maximum intensity is reached. It may be a clinically silent lesion but severe haematuria needing cauterisation or even cystectomy may occur.

As in some other normal tissues (oral mucosa, intestine and skin) expressing both early and late responses we have to consider the operation of two mechanisms for late bladder damage: (a) consequential late effect occurring as a consequence of early injury and (b) primary late effect occurring independently of early damage.

2.3.1- Consequential late bladder damage:

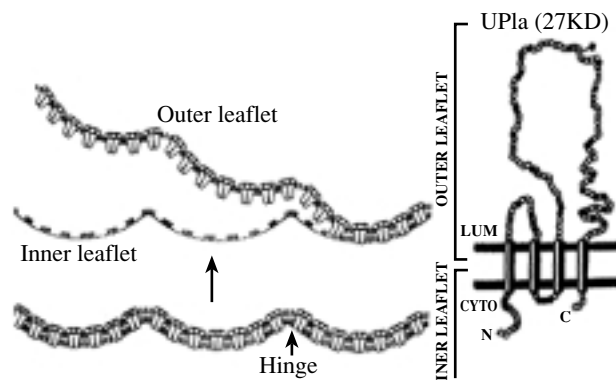


Fig. (1): The plasma membrane structure of the urothelium.

Left: Rigid plaques with "hinge zones" form the thick outer leaflet of the plasma membrane and are anchored to a thinner inner lipid bilayer. For illustration the two leaflets which are anchored to each other in the lower view are detached from each other in the upper view (Modified from Sun et al. 1999).

Right: A typical uroplakin molecule that maintains the urothelium membrane structure. The molecule has three domains. The luminal domain is the most bulky and constitutes the outer thick leaflet of the plasma membrane. The transmembrane domain serves to anchor it to the cytoplasm and to connect it to the cytoplasmic domain which is the shortest of the three domains. (Modified from Yu et al. 1994).

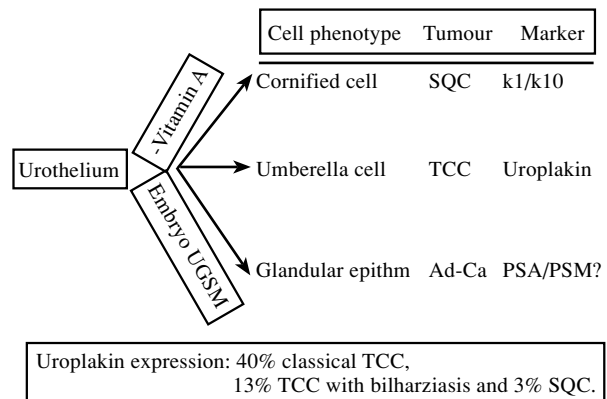


Fig. (2): Alternative pathways for urothelial differentiation and the cell type of the tumour that can arise from each cell type along with the specific markers. Embryo UGSM = embryonic urogenital sinus mesenchyme - PSA = Prostate specific antigen-(modified from Wu et al., 1998).

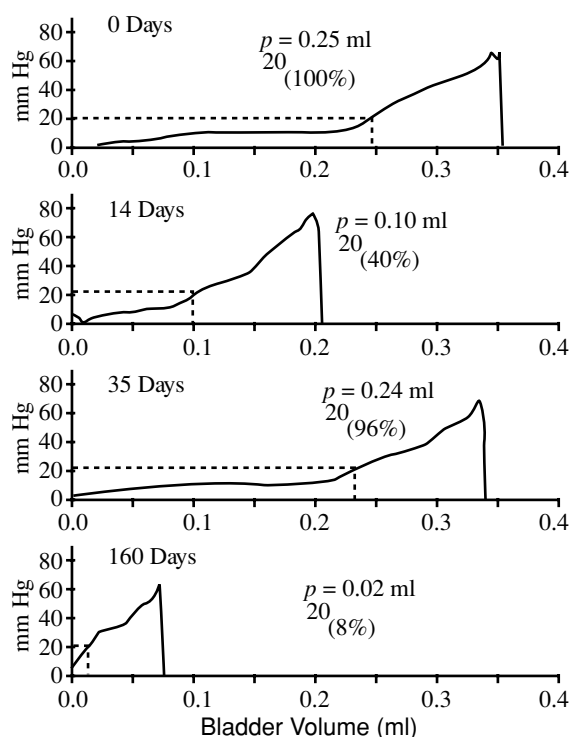


Fig. (3): The influence of a single 20 Gy dose on the bladder reservoir function in the same mouse. (A) Control pre-treatment curve. An initial small rise is followed by a flat phase corresponding to the normal bladder volume compliance, followed by a rise as the compliance is exceeded and a sharp drop due to passive leakage. (B) 14 days after irradiation at the peak of acute cystitis. The compliance phase is lost leading to an irritated bladder of a small volume. (C) After 35 days the compliance is nearly completely regained. (D) The final irreversible late damage with permanent loss of compliance after a latency of 160 days (After Lundbeck, 1993).

The possibility of existence of consequential late damage is suggested by the demonstration of a significant correlation between the second wave (16-30 days) of early damage and late changes in the urothelium of the same animal [12]. Mice developing an acute response during the 16-30 days period of acute response had an 80% risk of developing late damage compared with only 33% in absence of such an acute response. Compared to mice not showing an acute response, a highly significant increase in chronic functional impairment has been recorded in mice expressing such an acute response. In skin, bowel and oral mucosa, loss of the protective epithelial barrier during the acute phase is thought to underlie the consequential late damage in these tissues [10,11]. Such an epithelial denudement is not, however known to occur during acute cystitis. It can be postulated that, in the urinary bladder, the metabolic intracellular changes reported to occur during acute cystitis

rather than a physical barrier insufficiency can develop into chronic late consequential functional impairment [12].

### 2.3.2- Primary (generic) late effects:

There is also strong evidence that late damage can arise independently of early damage. Damage of two cell populations may be implicated in the late-occurring radiation bladder damage:

1- According to classical radiobiology concepts, damage to the slowly proliferating urothelium can be implicated in the genesis of late bladder damage. The occurrence of late radiation reactions would then be related to the slow turnover rate of urothelial cells since mitotic cell death does not occur except when the cell enters a division cycle. This interpretation seems to be still valid at least partly. The pattern of bladder damage induced by a combination of radiotherapy and cyclophosphamide (CY) seems to support the role of mitotic cell death in the genesis of late reactions [18,42]. In the mouse model, no manifestations of bladder damage were detectable 3 months after irradiation. However, when CY was given before the expression of late damage, the severity of drug-induced damage was appreciably greater than that expected from CY alone. As mentioned before, CY induces an early epithelial cell damage soon followed by a proliferative response. The latter response may then precipitate an early expression of latent radiation damage. Moreover, when CY was administered one month prior to irradiation an early expression of the radiation damage was noted. This suggests that radiation coincided with the time when active proliferation was taking place in response to chemical injury. This early expression was still evident when CY was given 6-9 m before irradiation indicating that the chemically induced regenerative response is long-lasting.

2- In combined CY-radiation experiments, the early expression of radiation damage induced by prior CY administration did not prevent the occurrence of a late damage 6-9 m after irradiation which occurred as a second wave of injury. This suggests the implication of a second cell population other than the bladder urothelium, which could well be represented by the endothelial cells and the cells of the fibromuscular coat. As in the case of a number of other late reacting tissues, recent studies demonstrated a progressive increase in the expression of TGF-

$\beta$  in the submucosa of irradiated bladder between 90 and 360 d after irradiation [28]. This was associated with promotion of production of the interstitial matrix and collagen types I and III along with increased bladder rigidity and reduced storage capacity. The vascular smooth muscle cells appear to contribute, at least in part, to production of TGF- $\beta$ .

### 2.3.3- Chronic low dose bladder exposure: The Chernobyl accident:

Since the Chernobyl nuclear power plant accident in 1986, about 10 million people are living in a radiocontaminated environment. These people have been chronically exposed to low radiation doses through the incorporated  $^{137}\text{Cs}$  and to lesser extent  $^{134}\text{Cs}$  which represent about 90% of the incorporated radioactivity. These radionuclides are excreted and concentrated in urine and thus leading to chronic low dose exposure of the urinary bladder. About 13 years after the accidents a study was performed on the urinary bladder urothelium of 42 patients living in Ukraine and having benign enlargement of the prostate [38]. Patients belonged to three groups as regards the level of radiation exposure: group I from a highly contaminated area (15 patients), group II from a less contaminated area (14 patients) while group III included a control group of 13 patients living in clean areas without radiocontamination. Radiation cystitis with multiple foci of severe dysplasia and carcinoma in situ were observed in 100% of subjects of group I and in 64% of subjects of group II with 4 small transitional cell carcinomas in both groups. The urothelial lesions of groups I and II showed a strong over-expression of stable p53 and p53 mutational inactivation. The bladder urothelial lesions of these two groups also showed elevated levels of inducible nitric oxide synthase (iNOS) and cyclooxygenase 2 in addition to overexpression of p53 [47]. Moreover the oxidative stress associated with long-term low radiation dose exposure has been shown to activate DNA damage repair (base and nucleotide excision repair) [39]. These features indicate a significant predisposition to bladder carcinogenesis.

### 2.3.4- Some therapeutic measures for the treatment of chronic radiation cystitis:

Severe haemorrhagic cystitis following pelvic irradiation is a relatively rare event. Its incidence tends to increase with time and is usually quoted as less than 5%. Its severity also increases with

time [9]. Various intravesical procedures have been tried to control bleeding from haemorrhagic cystitis and telangiectasis. These include cauterization, simple intravesical saline irrigation, alum, prostaglandin E1 and oestrogen. Topical application of formalin has been used in localized bleeding refractory to such measures. This involves application for 15 min of cotton pledges soaked in 5% formalin [31]. One study reported a long-term bleeding control for 14 months after this procedure [32].

Endothelial cell damage with decreased vascularity and oxygenation and impaired healing is an important component of chronic radiation cystitis. Hyperbaric oxygen (HBO) therapy has been successfully used to improve angiogenesis and promote healing in radiation-injured tissues. HBO has been used in the treatment of haemorrhagic cystitis after irradiation alone or in combination with cyclophosphamide [21]. Complete resolution of haematuria has been reported in about two thirds of patients [34]. HBO has been particularly successful in haemorrhagic cystitis complicating allogeneic bone marrow transplantation [24,37]. Though long-term remissions have been reported, remissions are often of short duration. It is advisable not to delay HBO treatment in order to avoid extensive bladder fibrosis and shrinkage. HBO is recommended to be used at a pressure of 2.2-2.4 atmospheres for 60 min every day until haematuria resolves or becomes stationary. Chronic proctitis can also complicate pelvic irradiation either alone or in association with haemorrhagic cystitis. HBO also proved to be effective against radiation proctitis [35,20].

### 2.4- Bladder response to multifraction irradiation:

Multifraction radiation experiments revealed that the UB can repair sublethal damage to a greater extent than the skin but less than lung or kidney. For late bladder injury in the mouse model, analysis of isoeffective total doses in multifraction irradiation regimens yielded an  $\alpha/\beta$  ratio of 5.8 Gy which is intermediate between the values for early and late reacting tissues [3]. It seems, therefore, that late injury in the mouse bladder is one of the least sensitive late reactions as regards dependence on the fraction size [13]. This has to be taken into account when investigating hyperfractionation radiotherapy regimes involving reduction of the fraction size in attempt at escalating the total dose. Using

early reactions as an end-point, multifraction radiation experiments yielded an  $\alpha/\beta$  ratio of 11-12 Gy which is similar to that of other early reacting tissues [15]. This finding is difficult to interpret in the light of the fact that early bladder reactions are not associated with mitotic cell kill.

As expected from the slow turnover rate and the late occurrence of a regenerative response, bladder damage after a multifraction irradiation is not appreciably dependent on the overall treatment time unless (a) mucosal hyperplastic changes are already present prior to irradiation, e.g. in bladders suffering of chronic or parasitic infection, or (b) there is a significant consequential late effect.

### REFERENCES

- 1- Awwad H.K., Akoush H., El-Merzabani M., El-Badawy S. and Barsoum M. El-Baki H.: Experience in radical radiotherapy of cancer in the bilharzial bladder: the use of misonidazole. *Radiother. Oncol.*, 2: 1-8, 1984.
- 2- Awwad H.K., Hegazy M., El-Bolkainy N. and Burgers M.V.: Cell proliferation of carcinoma in bilharzial bladder an autoradiographic study. *Cell Tissue Kinet.*, 2: 513-520, 1979.
- 3- Bentzen S.M., Lundbeck F., Christensen L.L. and Overgaard J.: Fractionation sensitivity and latency of late radiation injury to the mouse urinary bladder. *Radiother. Oncol.*, 25: 301-307, 1992.
- 4- Baker P.M. and Young R.H.: Radiation-induced psudocarcinomatous proliferations of the urinary bladder: a report of 4 cases. *Hum. Pathol.*, 31: 678-683, 2000.
- 5- Bullock P.S., Thoni D.E. and Murphy W.M.: The significance of colonic mucosa (intestinal metaplasia) involving the urinary tract. *Cancer*, 59: 2086-2090, 1987.
- 6- Chang A., Hammond T.G., Sun T.T. and Zeidel M.L.: Permeability properties of the mammalian bladder apical membrane. *Ann. J. Physiol.*, 267: C1483-C1492, 1994.
- 7- Conha G.R., Fujll H., Neubauer B.L., Shannon J.M., Sawyer L. and Reese B.A.: Epithelial-mesenchymal interactions in prostate development. I. Morphological observations of prostatic induction by urogenital sinus mesenchyme in epithelium of the adult rodent urinary bladder. *J. Cell Biol.*, 96: 1662-1670, 1983.
- 8- Cox P.J.: Cyclophosphamide cystitis: identification of acrolein as the causative agent. *Biochem. Pharmacol.*, 28: 2945-2949, 1979.
- 9- Crew J.P., Jephcott C.R. and Reynard J.M.: Radiation-induced haemorrhagic cystitis. *Eurp. Urol.*, 40: 111-123, 2001.
- 10- Denham J.W., Hauer-Jensen M., Kron T. and Langberg C.W.: Treatment-time-dependence models of early and delayed radiation injury in rat small intestine. *Int. J. Radiat. Oncol. Biol. Phys.*, 48: 871-878, 2000.
- 11- Denham J.W., Peters L.J., Johansen J., Poulsen M., Lamb D.S., Hindley A., O'Brien P.C., Spry N.A., Penniment M, Krawitz H., Williamson S., Bear J. and Tripcony L.: Do acute mucosal reactions lead to consequential late reactions in patients with head and neck cancer? *Radiother. Oncol.*, 52: 157-164, 1999.
- 12- Dörr W. and Beck-Bornholdt H.P.: Radiation-induced impairment of urinary bladder function in mice: fine structure of the acute response and consequences on late effects. *Radiat. Res.*, 151: 461-467, 1999.
- 13- Dörr W., Bentzen S.M.: Late functional response of mouse urinary bladder to fractionated X-irradiation. *Int. J. Radiat. Biol.*, 75: 1307-1215, 1999.
- 14- Dörr W., Eckhardt M., Ehmea and Koi S.: Pathogenesis of acute radiation effects in the urinary bladder Experiment results. *Strahlentherapie und Onkologie*, 174 (Suppl III): 93-95, 1998.
- 15- Dörr W., Feudel R. and Schultz-Hector S.: Early responses of mouse urinary bladder to dose fractionation. *Radiother. Oncol.*, 24, Suppl. S19, 1992.
- 16- Eckhardt M. and Dorr W.: Changes in expression of urothelial proteins during the acute radiation response of murine urinary bladder. ESTRO 1998 Conference, Edinburgh abstract number, 266, 1998.
- 17- Eckhardt M., Kasper M. and Dorr W.: Morphological changes accompanying the acute functional response of the urinary bladder to irradiation. 45th Annual Meeting of the RRS, Privence Road Island, USA, May, Book of abstracts p 195, 1997.
- 18- Edrees G., Luts A. and Stewart F.: Bladder damage in mice after combined treatment with cyclophosphamide and X-rays: influence of timing and sequence. *Radiother. Oncol.*, 11: 349-360, 1988.
- 19- El-Aasar A.A., El-Merzabani M., Abdel-Reheem K.A. and Hamza B.M.: A study on the etiological factors of bilharzial bladder cancer in Egypt: 4 beta-carotene and vitamin A level in serum. *Tumori*, 68: 19-22, 1982.
- 20- Ennis R.D.: Hyperbaric oxygen for treatment of radiation cystitis and proctitis. *Curr. Urol. Rep.*, 3: 229-231, 2002.
- 21- Feldmeier J.J. and Hampson N.B.: A systematic review of the literature reporting the application of hyperbaric oxygen prevention and treatment of delayed radiation injuries: an evidence based approach. *Undersea Hyperb. Med.*, 29: 4-30, 2002.
- 22- Galvin S., Loomis C., Manabe M., Dhoulailly D. and Sun T.T.: The major pathology of keratinocyte differentiation as defined by keratin expression: an overview. *Adv. Dermatol.*, 4: 277-299, 1989.
- 23- Gaugler M.H., Squiban C., van der Meeren A., Bertho J.M., Vandamme M. and Mouthon M.A.: Late and persistent up-regulation of intercellular adhesion molecule-1 (ICAM-1) expression by ionizing radiation in human endothelial cells in vitro. *Int. J. Radiat. Biol.*, 72: 201-209, 1997
- 24- Hattori K., Yabe M., Matsumoto M., Kudo Y., Yasuda

- Y., Inoue H., Minami S., Miyakita H., Kawamura N., Komori K., Yamamoto I. & Yabe H.: Successful hyperbaric oxygen treatment of life-threatening hemorrhagic cystitis after allogeneic bone marrow transplantation. *Bone Marrow Transplant*, 27: 1513-1517, 2001.
- 25- Islam R., Isaacson B.J., Zickerman P.M., Ratanawong C. and Tipping S.J.: Hemorrhagic cystitis as an unexpected adverse reaction to temozolomide: case report. *Am. J. Clin. Oncol.*, 25: 513-514, 2002.
- 26- Jaal J. and Dörr W.: Acute radiation effects in the urinary bladder (mouse) urothelial cell density and expression of ICAM-1. *Radiother. Oncol.* 64 (suppl 1) S191 (Abstract), 2002.
- 27- Kachar B., Liang F., Lins U., Dins M., Wu X.R., Stoffler F., Aebi U. and Sun T.T.: Three-dimensional analysis of the 16-nm urothelial plaque particle: luminal surface exposure, preferential head-to-head interaction, and hinge formation. *J. Mol. Biol.*, 285: 595-608, 1999.
- 28- Kraft M., Oussoren F., Stewart F.A., Dörr W. and Schultz-Hector S.: Radiation-induced changes on transforming growth factor  $\beta$  and collagen expression in murine bladder wall. *Radiat Res* 146:619-627, 1996.
- 29- Liang F., Kachar B., Ding M., Zhai Z., Wu R.U. & Sun T.T.: Urothelial hinge as a highly specialized membrane: detergent insolubility, urohingin association and in vitro formation. *Differentiation*, 65: 59-69, 1999.
- 30- Liebhold W., Wendi M., Kaup F.J. and Drommer W.: Light and electron-microscopic studies of structure of normal bladder epithelium in female swine. *Anat. Histol. Embryol.*, 24: 47-52, 1995.
- 31- Lojanapiwat B., Sripralakit S., Soonthornphan S. and Wudhikarn S.: Intravesical formalin instillation with a modified technique for controlling haemorrhage secondary to radiation cystitis. *Asian. J. Surg.*, 25: 232-235, 2002.
- 32- Lowe B.A. and Stamey T.A.: Endoscopic topical placement of formalin soaked pledges to control localised hemorrhage due to radiation cystitis. *J. Urol.*, 58: 528-529, 1997.
- 33- Lundbeck F.: A experimental in vivo model in mice to evaluate the change in reservoir function of the urinary bladder due to irradiation alone or combined with chemotherapy. *Recent Results Cancer Res.*, 130: 89-102, 1993.
- 34- Mathews R., Rajan N., Josefson I., Caporesi E. and Makhuli Z.: Hyperbaric oxygen therapy for radiation-induced hemorrhagic cystitis. *J. Urol.*, 161: 435-437, 1999.
- 35- Mayer R., Klemen H., Quehenberger F., Sankin O., Mayer E., Hackl A. and Smolle-Juettner F.M.: Hyperbaric oxygen-an effective tool to treat radiation morbidity in prostate cancer. *Radiother. Oncol.*, 61: 151-156, 2001.
- 36- Molloy C.J. and Laskin L.D.: Effect of retinoid deficiency on keratin repression in mouse bladder. *Exp. Mol. Pathol.*, 49: 128-140, 1988.
- 37- Plafki C., Carl U.M., Glag M. and Hartmann K.A.: The treatment of late radiation effects with hyperbaric oxygen. *Stahlether. Oncol.*, 3: 66-68.
- 38- Romanenko A., Morimura K., Wanibuchi H., Salim E.I., Kinoshita A., Maneko M., Vozianov A. and Fukushima S.: Increased oxidative stress with gene alteration in urinary bladder urothelium after Chernobyl accident. *Int. J. Cancer*, 86: 790-798, 2000.
- 39- Romanenko A., Morimura K., Wei M., Zaporin W., Vozianov A. and Fukushima S.: DNA damage repair in bladder urothelium after the Chernobyl accident. *J. Urol.*, 168: 973-977, 2002.
- 40- Schoenike S.E. and Dana W.J.: Ifosfamide and mesna. *Clin. Phar.*, 9: 179-183, 1990.
- 41- Shaw I.C. and Graham M.I.: Mesna: a short review. *Cancer Treat. Rev.*, 14: 67-72, 1987.
- 42- Stewart F.: Mechanism of bladder damage and repair after treatment with radiation and cytotoxic drugs. *Br. J. Cancer (Suppl. VII)*: 280-291, 1986.
- 43- Srivastava A., Nair S.C., Srivastava V.M., Balamurugan A.N., Jeyaseelan L., Chandy M. and Gunasekaran S.: Evaluation of uroprotective efficacy of amifostine against cyclophosphamide induced hemorrhagic cystitis. *Bone Marrow Transplantation*, 23: 463-467, 1999.
- 44- Sun T.T., Liang F.X. and Wu X.R.: Uroplakins as markers of urothelial differentiation. In: Baskir L.S., Hayward M. (Eds) *Advances in bladder research*. Kluwer Academic/Plenum, New York pp.7-18, 1999.
- 45- Wu R.L., Osman I., Wu X.R., Lu M.L., Zhang Z.F., Liang F.X., Hamza R., Scher H., Cordon-Cardo C. and Sun T.T.: Uroplakin II gene is expressed in transitional cell carcinoma but not in Bilharzial bladder squamous carcinoma alternative pathways of bladder epithelial differentiation and tumor formation. *Cancer Res.*, 58: 1291-1297, 1998.
- 46- Wu X.R., Medina J.J. and Sun T.T.: Selective interactions of UPIa and UPIb, two members of the transmembrane 4 superfamily, with distinct transmembrane-dominated proteins in differentiated urothelial cells. *J. Biol. Chem.*, 27: 29752-29759, 1995.
- 47- Yamamoto S., Romanenko A., Wei M., Masuda C., Zaporin W., Vinnichenko W., Vozianov A., Lee C.C., Morimura K., Wanibuchi H., Tada M. and Fukushima S.: Specific p53 gene mutations in urinary bladder epithelium after the Chernobyl accident. *Cancer Res.*, 59: 3606-3609, 1999.
- 48- Yu J., Manabe M. and Sun T.T.: Identification of an 85-100 kDa glycoprotein as a cell surface marker for an advanced stage of urothelial differentiation: association with inter-plaque ('hinge') area. *Epithelial Cell Biol.*, 1: 4-12, 1992.
- 49- Yu J., Lin J.H., Wu X.R. and Sun T.T.: Uroplakin Ia and Ib, two major differentiation products of bladder epithelium, belongs to a family of four transmembrane domain (4TM) proteins. *J. Cell Biol.*, 125: 1712-182, 1994.