

The Versatile Naso-Labial Flaps in Facial Reconstruction

HAMDY H. EL-MARAKBY, M.D., F.R.C.S.

The Departments of National Cancer Institute, Cairo University.

ABSTRACT

Background: Surgical excision of tumors from the face may create a defect that is difficult to restore. Skin grafts can only cover superficial defects and has a natural tendency to contract and may not take properly. Also, because of the colour mismatch, it is not cosmetically identical to the face. The use of regional flaps such as the median forehead flaps are usually bulky, can not cover a wide range of facial reconstruction and usually require the donor area to be grafted. The naso-labial flaps are very useful and versatile local flaps, with robust vascularity that can be readily elevated without a delay. The flap can be superiorly based to reconstruct defects on the cheek, side wall or the dorsum of the nose, alae, collumula and the lower eye lid. Inferiorly based flaps can be used to reconstruct defects in the upper lip, anterior floor of the mouth and the lower lip. The flap can be turned over and used as a lining of the nose and the lip.

Aim of the Study: In the current study we present our experience with utilization of the nasolabial flaps in facial reconstruction. We evaluated the indications, flap designs, technique, and complications. We will also assess the final functional and aesthetic results.

Material and Methods: The study included 20 patients (12 males and 8 females) presented at the surgical department, National Cancer Institute (NCI) Cairo University with skin cancer at different areas of the face. Preoperative assessment includes. Assessment of the stage of the disease, the flap design and patient general condition.

Results: The mean age of the patients was 56.3±6 years (range 16-62 years). Fifteen patients presented with basal cell carcinoma, 2 squamous cell carcinoma, one malignant melanoma, one keratoacanthoma, and one xeroderma pigmentosa. Nasal defects constituted 75% of cases, the rest were lower eye lid (2), one upper lip and one oral commisure beside a case of cheek reconstruction. There was no major complication; only one patient suffered a reactionary hemorrhage that required re-exploration to secure the bleeder. A single procedure was adequate in most of the patients (80%), only 4 patients required revision of the scar at the donor site. The overall aesthetic results were very satisfactory in the majority of patients (16), and satisfactory in 2 cases. Only 2 patients were not

satisfied by the final aesthetic results, one suffered from ectropion and the other had a donor site wound healing problem.

Conclusion: The nasolabial flap is a versatile, simple, easy to harvest local flap that can cover a variety of defects in the face. It is ideally suitable for covering small and moderate sized defects in the eye lid, cheek, nose, the anterior floor of the mouth and the lip.

Key Words: Nasolabial - Facial reconstruction - Nasal reconstruction.

INTRODUCTION

Defects in the cheek, nose, lip and the eye lid can create a challenge to the reconstructive surgeon. This is due to the functional and the aesthetic problems occurring as a result of resection of tumors in these areas. The cheek and forehead areas are considered the best donor areas to cover such defects because of their proximity, the colour match and the simplicity of transfer to the recipient areas in the face [1]. There is an area of redundancy that extends from the inner canthus to the inferior margin of the mandible, especially in old patients. This area is generally hairless except for the lower cheek in males and is considered the donor area for the nasolabial flaps.

Superiorly based naso-labial flaps can be used for reconstruction of nasal defects, lower eye lid, and the cheek except for the most cephalad part of the nose. The flap tissues are considered ideal when there is a full thickness deformity of the nose or when there is an exposed cartilage or bone. Inferiorly based flaps are considered useful in reconstruction of the lip, oral commisure and the anterior oral cavity [2].

Nasolabial flaps can be used to reconstruct the ala of the nose, where a local turn over flap with or without a cartilage can be utilized [3,4]. Narrow flaps can be used to reconstruct an alar rim deformity such as those seen with facial burn. Although the reconstruction of the columella can be obstinate because of the difficulty in duplicating the nasal flare, the passage of a superiorly based naso-labial flap through an incision in the alar crease allows the placement of the flap about the columella [4].

The vascular anatomy of the nasolabial flaps is based on the angular artery (a branch from the anterior facial artery), the infra-orbital artery, the transverse facial artery and the infratrochlear artery. Because of the rich vascular supplies and the free anastomosis between the terminal branches of the supplying vessels of the flap; superior, inferior, medial, and lateral based flaps can be raised [5]. Due to rich sub dermal plexus the flap can be used either a random flap based or as axial pattern flap. A subcutaneous pedicled flap can be also raised as laterally or inferiorly based [6].

The flap design, size and dimensions are limited to the redundancy of available tissues and the possibility of closing the donor site primarily without deformity. Superiorly and medial based flaps are limited in width (as much as 5cm) where their length can reach up to 10-12cm [7]. On the other hand, inferiorly based flaps are usually of limited length, where tissues based laterally and advanced into the nose are most restricted by the available redundancy between the inner canthus and the nasolabial fold [8].

The orientation of the pedicle is usually determined by the location of the defect and the requirement of rotation or advancement of appropriate tissues to the defect. The flap thickness is also determined by the needs of the defect as well as the thickness of the donor tissues. The flap can be as thin as deep to the sub dermal plexus, and as thick as superficial to the facial musculature with their nerve supply intact [9].

The flap elevation can be easily done under local anaesthesia in adults. The area surrounding the nasolabial fold is usually infiltrated with 1% xylocaine with epinephrine 1:100000. The plane of dissection starts distally and, 100.000

is usually beneath the subcutaneous fat of the flap and superficial to the underlying musculature. The adjacent tissues of the cheek are widely undermined for closure of the donor site in the nasolabial fold [10].

When designed as a pedicled flap, the nasolabial flap can be detached between 10 and 21 days and the remaining flap can be reinserted into the cheek. Defatting of the flap may be required especially in people with much fatty tissues in their face to establish the smoothness of the nasolabial folds. A cartilage taken from the ear or the septum of the nose may be inserted at a later date for support [11].

PATIENTS AND METHODS

The study included 20 patients with different facial potential defects as a result of resection of skin cancer presented at the surgical department, NCI Cairo University during the last 3 years (2002-2005). Patients were prospectively evaluated for suitability to nasolabial flap reconstructive technique by measuring the potential defect size, site and depth. All the defects were either small to moderate sized (2-4cm in width), full thickness and affected different areas in the face such as the lower eye lid, nose, lips, oral commissure and the cheek.

Patients who were diagnosed with skin cancer i.e. melanoma and squamous cell carcinoma were assessed for evidence of metastasis in the lung or the liver by chest X-ray and abdominal sonar. Bleeding and coagulation profiles, ECG, liver and kidney functions tests were routinely performed for all patients prior to surgery.

The reconstructive technique, procedure and the flap design was thoroughly discussed with the patients in the pre assessment clinic. Also, pre operative photos were routinely taken immediately prior to surgery. An informed consent was signed by the patient and countersigned by the reconstructive surgeon undertaking the procedure.

The technique of anaesthesia, the flap design, and the duration of operation all were recorded. Postoperatively; the flap was monitored for the colour changes, temperature and the capillary filling time. The postoperative complications and the length of hospital stay were documented.

Postoperative photos in addition to an independent surgical opinion were used to assess the final cosmetic results as well as the functional results of the reconstruction. Four outcome measures were used for assessment and subjectively evaluated. These were the percentage of flap contraction, the degree of colour match, the donor site morbidity and the functional outcome.

RESULTS

A total of 20 consecutive patients were subjected to nasolabial flap reconstruction for different facial defects. The male to female ratio was 3:2 and the mean age was 56.3 ± 6 years, and the range was 16-62 years. The majority of facial defects were nasal (75%), whereas the rest of defects were 2 lower eye lid, one upper lip, one oral commissure and one cheek (Figs. 1-4). The majority of defects were due to basal cell carcinoma (15 cases) representing 75%, 2 squamous cell carcinoma, one melanoma, one keratoacanthoma and one xeroderma pigmentosa.

The majority of patients underwent the procedure under local anaesthesia by using xylocaine 1%, adrenaline 1/200000 combinations. However, in 4 patients (20%) the procedure was carried out under general anaesthesia either due to the extent of the defect in 2 patients, in one patient due to the critical general medical condition and in another patient because of his own preference.

A superiorly based flap was performed in 16 (80%) patients whereas an inferiorly based flap was performed in 3 patients and an advanced nasal cheek flap was done in one patient. The mean operative time was 35 minutes, ± 10.5 and the range was 26-46 minutes. No single patient required a blood transfusion and all patients were discharged next morning. There were no reported major complications, only one patient required re exploration 4 hours after surgery for reactionary hemorrhage. This patient was known to suffer from a low platelet count preoperatively that resulted in a haematoma after operation.

There were no reported cases of wound infection, scar contraction or major donor site morbidity. The procedure was carried out as a single stage one in the majority of cases; only

4 patients required a revisional surgery for flap adjustments and correction of a dog ear in the donor site, 4 weeks after surgery.

All patients were followed up for an average of 8 months postoperatively, range (5-14 months). There was no single case of tumor recurrence underneath the flap or distant metastasis.

The overall results were either satisfactory or very satisfactory in 90% of patients (Figs. 1-4). Only 2 patients suffered minor complications, their score were fair results by the independent observer aided by the final postoperative photos.

DISCUSSION

The versatility and the usefulness of nasolabial flaps are well recognized in the reconstruction of the nose. When it is used to resurface the nose it should be based superiorly on the angular vessels and swung like a pendulum rather than a rotation flap to avoid the occurrence of dog ear deformity [1]. da Silva [2] modified the classical superiorly based flap by tunneling it transversely for collumular reconstruction. However, a second stage division of the flap was required after 2-3 weeks. Kaplan [3] on the other hand, based the flap inferiorly and used it as a bilateral island flap for collumular reconstruction. This avoided the second stage division of the flap or the dog ear deformity. In the present study, most of the flaps were superiorly based and were performed as a single stage procedure in 80% of cases with only one case of dog ear deformity that required reshaping 4 weeks after surgery.

The flap can be also based inferiorly to repair small and medium sized defects on the lip and the floor of the mouth with satisfactory aesthetic and functional results [9,12]. The subcutaneous pedicled flaps have been recently used to reconstruct a defect in the lower eye lid in combination with tarso-conjunctival defects that was reconstructed by a cartilage transfer from the nasal septum [13]. In one of our cases, we used the flap in combination with a cartilage harvested from the post auricular region to reconstruct a full thickness defect in the lower eye lid (Fig. 3). The functional result for such case was very satisfactory with no ectropion deformity.

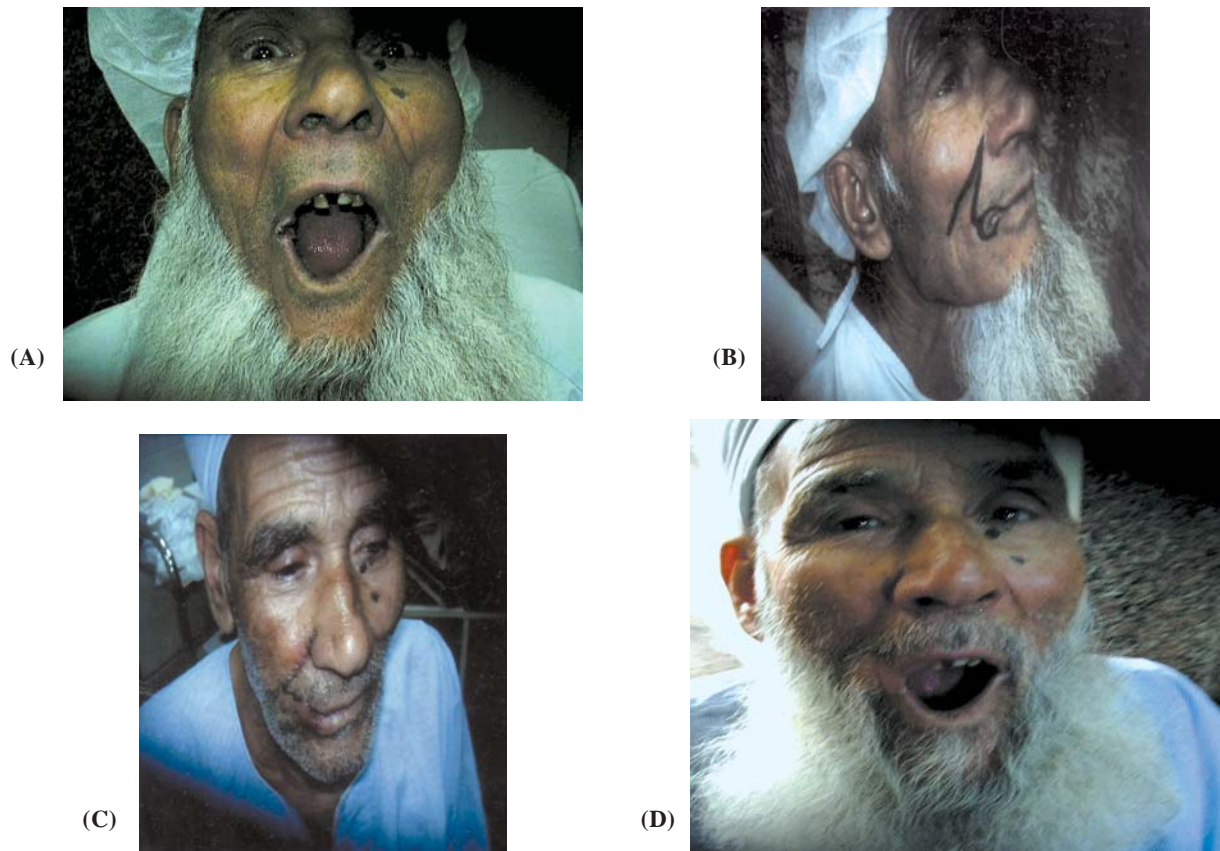

Fig. (1): A- Preoperative picture of a defect in the right lip commissure. B- An inferiorly based nasolabial flap C- Immediate postoperative picture. D- Late postoperative picture shows normal competence of the oral commissure.

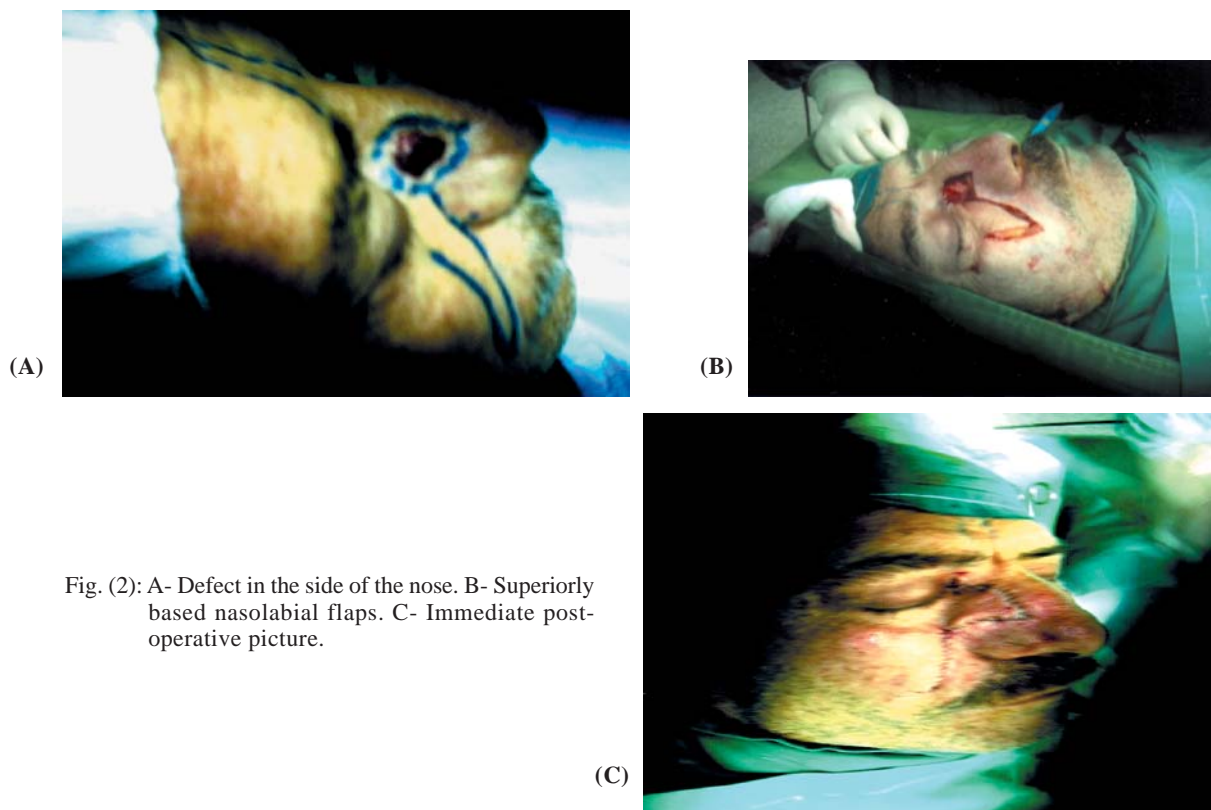


Fig. (2): A- Defect in the side of the nose. B- Superiorly based nasolabial flaps. C- Immediate post-operative picture.

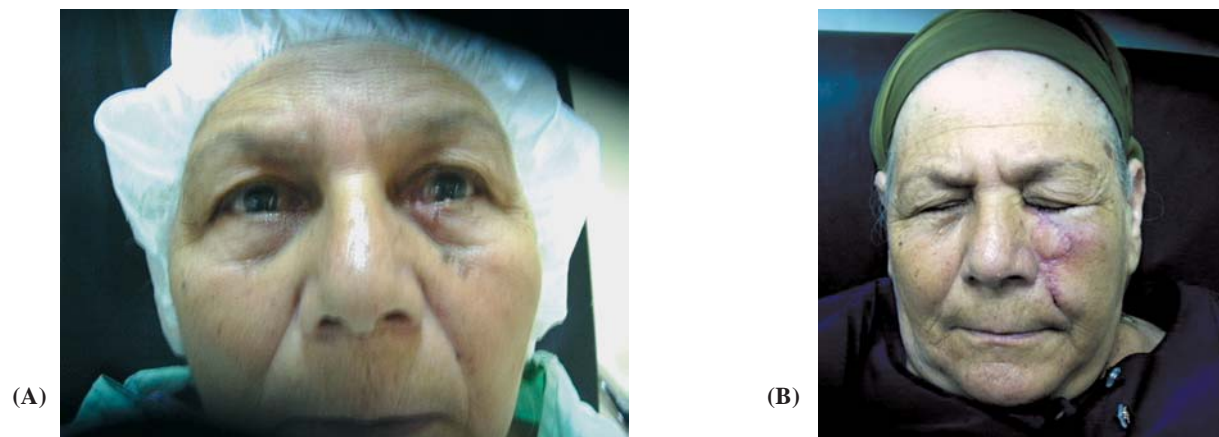


Fig. (3): A- Basal cell carcinoma in the inner aspect of the lower eye lid. B- Early postoperative picture after excision and repair with a superiorly based nasolabial flap.

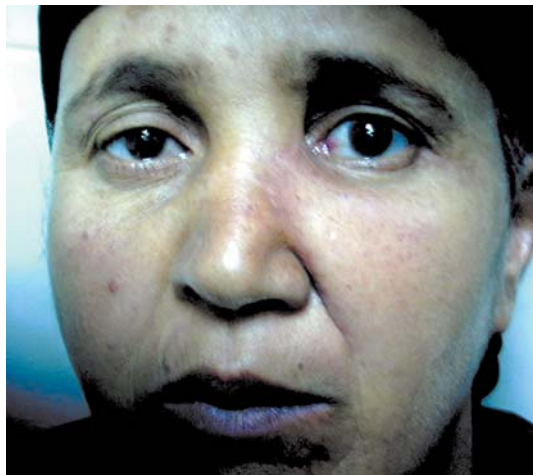

Fig. (4). The final aesthetic result after an advancement nasal check flap. There is no scar contracture, donor site morbidity or functional disability with a very good colour match.

The advantages of using the nasolabial flap; in addition to the robust vascularity; include the simplicity and the time saving that the procedure provides. The proximity to the recipient defects, the best colour match and the satisfactory contour created from the relatively hairless areas utilized from the nasolabial fold are the other major advantages of the technique. In the current study, most of the flaps were raised under local anesthesia, with a short procedure time (26-46 minutes), a result that matches others' experiences [1,2,3].

The higher vascularity of the flap and the less donor site morbidity compared with the median forehead flap makes it a superior alternative in facial reconstruction. However, the

limitations of the flap use include; the limited flap size, width and the limited arc of rotation. This makes it only suitable for small and medium sized defects. The flap has been recently used to reconstruct defects in the anterior floor of mouth [9,12], an application that has not been tested in the current study.

With regard to the complications, we did not report any major complications from the flap utilizations, a result that matches other experience [2,3,5]. However, there was no need for a second stage procedure in the majority of our cases.

The loss of the nasal cheek junction as a result of recruiting such area in the flap design and the donor site morbidity (dog ear) are among the few side effects of the flap use [2]. Although the majority of the flap in our series were used as a single procedure, a second procedure for flap adjustments and/or excision of a dog ear was necessary in 2 patients. Matching the size and the depth of the defect with partial de-epithelialization and immediate defatting of the flap may alleviate such problem.

The cosmetic outcome of reconstruction is usually affected by the number of procedures required to reach the final results, the rate of complications, donor site morbidity, the percentage of flap contraction and the degree of colour match. All of these parameters were subjectively favorable in the majority of our cases. This encourages the future wider application of the flap in the reconstruction of other areas of the face including the floor of the mouth, the hard palate and the lower lip.

Conclusion:

The versatility of nasolabial flaps exceeds its recognized application in nasal defects reconstruction. It can be a useful procedure in reconstructing a cheek, eye lid, lip and floor of mouth defects. Although the flap size can be a limiting factor in the flap utilization in reconstructing facial defects, it can be used to cover defects as wide as 5cm. In spite of the recently reported studies of the flap use in the reconstruction of the floor of the mouth, we did not test such application in the current study. A larger series of patients and wider applications can be evaluated in the future.

REFERENCES

- 1- Cameron RR. Nasolabial and cheek flaps. Grabb's Encyclopedia of flaps, 2nd ed. B. Straunch, L.O. Vanconez and E.J. Hall-Findlay. Eds. Lippincott-Raven. Philadelphia. 1998, 1: 56-61
- 2- da Silva GA. A new method of reconstructing the columella with a nasolabial flap. *Plast Reconstr Surg.* 1964, 34: 63.
- 3- Kaplan I. Reconstruction of the collumella. *Br J Plast Surg.* 1972, 25: 37.
- 4- Yanai A, Nagata S, Tanaka H. Reconstruction of the collumella with bilateral nasolabial flaps. *Plast Reconstr Surg.* 1986, 77: 129.
- 5- Ohtsuka H. Nasolabial flaps to the cheek. Grabb's Encyclopedia of flaps, 2nd ed. B. Straunch, L.O. Vanconez and E.J. Hall-Findlay. Eds. Lippincott-Raven. Philadelphia. 1998, 375-377.
- 6- Barron JN. Subcutaneous pedicle skin flaps. Grabb's Encyclopedia of flaps, 2nd ed. B. Straunch, L.O. Vanconez and E.J. Hall-Findlay. Eds. Lippincott-Raven. Philadelphia. 1998, 167-173.
- 7- Kaluzinski E, Crasson F, Alix T, Labbe D. Nasolabial flap reconstruction of the collumella. *Rev Stomatol Chir Maxillofac.* 2004, 105: 171.
- 8- Ran W, Fan X, Tan Z, Ni S. Clinical application of a retrograde nasolabial fold island flap based on the upper labial artery. *Zhonghua Zheng Xing Wai ke Za Zhi.* 2002, 18: 25.
- 9- Varghese BT, Sebastian P, Cherian T, Mohan PM, Ahmed I, Koshy C, et al. Nasolabial flaps in oral reconstruction: an analysis of 224 cases. *Br J Plast Surg.* 2001, 54: 499.
- 10- Paletta CE, Paletta FX. Nasolabial skin flap to the lower eye lid. Grabb's Encyclopedia of flaps, 2nd ed. B. Straunch, L.O. Vanconez and E.J. Hall-Findlay. Eds. Lippincott-Raven. Philadelphia. 1998, 84.
- 11- Rohrich RJ, Conrad MH. The superiorly based nasolabial flap for simultaneous alar and cheek reconstruction. *Plat Reconstr Surg.* 2001, 108: 1727.
- 12- Maurer P, Eckert AW, Otto C, Schubert J. Reconstruction of the mouth with nasolabial flaps. Report of 10 years experience. *Schweiz Monatsschr Zahnmed.* 2002, 112: 463.
- 13- Tei TM, Larsen J. Use of the subcutaneously based nasolabial flap in lower eye lid reconstruction. *Br J Plast Surg.* 2003, 56: 420.