

## Functional Evaluation of Modified T Pouch as Ileal Neobladder Orthotopic Reservoir

HISHAM M. HAMMOUDA, M.D.

The Department of From Urology, Assiut University, Assiut, Egypt.

### ABSTRACT

**Background and Objective:** We report on the functional results of orthotopic modified T pouch ileal neobladder, incorporating serous-lined extramural ileal antireflux technique for urinary diversion after radical cystectomy.

**Material and Methods:** From September 1998 through November 2001, 42 patients of mean age 49 years (range 45-54) having invasive bladder carcinoma underwent radical cystectomy and orthotopic ileal neobladder urinary diversion, the modified T pouch. Thirty-three patients were males while the remaining 9 were females. The mean follow up was 24 months (range 18-42). Preoperative uni- or bilateral ureteral dilatation was noted in 13/42 (30.9%) patients. Follow up included clinical examination, laboratory, radiological and urodynamic investigations.

**Results:** Early postoperative complications were recorded in 3 cases, that were managed conservatively. Day and night continence were achieved in 34/42 (81%) and 29/42 (69%) patients, night enuresis in 2 (4.8%), while satisfactory day and night continence were noted, respectively. Upper urinary tract (UUT) remained unchanged or improved in all cases. No need for clean intermittent catheterization (CIC). No evidence of reflux was detected. Pressure at maximum capacity (average 17cm H<sub>2</sub>O at 600ml). Mean flow rate was 17.6 ml/sec (range 15-24). Pelvic cancer recurrence was recorded in 5 patients at mean 24 months, respectively.

**Conclusions:** Modified T pouch has an excellent functional criteria as an orthotopic ileal neobladder reservoir. It is absolutely indicated in short and/or massively dilated ureter.

**Key Words:** Urinary diversion - Ileum - Bladder cancer.

### INTRODUCTION

During the last 10 years we have changed our techniques to create orthotopic ileal neobladder. We tried to choose the proper technique

that can provide best results. We used ileal neobladder described by Hautmann [1] Studer pouch [2] and M shaped neobladder incorporating serosal lined extramural tunnel technique [3] for ureteral anastomosis. During this experience we faced some difficulties associated with the reconstruction of M ileal neobladder with serosal lined extramural ureteral reimplantation. Those difficulties were due to short ileal mesentery [4,5] and grossly dilated and short ureters [6]. This resulted in difficult uretero and urethro-ileal anastomosis. Some surgical tricks [7] and modified techniques were described to overcome these difficulties [8-10], but they are still a matter of debate. In the current study we incorporated the technique described by Stein and associates [11] based on the principles of Abol-Enein and Ghoneim [3] and Mitrofanoff appendiceal sub-serosal tunnel [11] to M shaped ileal neobladder and termed it modified T pouch.

### MATERIAL AND METHODS

*Inclusion criteria for this prospective study were:*

- 1- Preoperative oral and written consent for urinary diversion after radical cystectomy in the form of modified T pouch with optional Charleston catheterizable pouch [12,13].
- 2- Organ confined, but muscle invasive bladder cancer not extended to posterior urethra in male or bladder neck in female.
- 3- Fitness for operation and availability for at least 18 months follow up.

From September 1998 through November 2001, 42 patients underwent radical cystectomy and orthotopic ileal neobladder (modified T pouch) at Urology Department, Assiut University Hospitals, Assiut, Egypt. A total of 42 patients with a mean age of 49 years old (range 45-54 years) underwent radical cystectomy and continent urinary diversion in the form of orthotopic ileal neobladder, the modified T pouch. Of our patients, 33 were males and 9 were females. Mean follow up was 24 months (range 18-42 months) Preoperative uni- or bilateral ureteral dilatation (confirmed by intraoperative caliber  $\geq$  14 Fr. catheter) were encountered in 13/42 (30.9%) patients. Histological patterns were squamous cell carcinoma of the bladder in 29 and transitional cell carcinoma in 13 patients. Radical cystectomy with en-bloc bilateral pelvic lymphadenectomy was performed [14,15]. Nerve sparing technique was adopted in 18/42 (54.5%) in selected males.

*Operative technique:* The modified T pouch is constructed from 48 cm of distal ileum. This segment is divided into distal 40 cm and proximal (afferent limb) 8 cm segments, each with a separate mesentery. Distal segment is then laid out in M configuration with 4 equal 10 cm limbs. Adjacent limbs are approximated by 3/0 interrupted seromuscular silk sutures. Anti – mesenteric border is incised by diathermy knife. Mucosa of adjacent limbs are approximated by continuous 3/0 polyglycolic sutures. Distal 4cm of afferent limb is tailored over a 30 Fr. catheter, closed by one layer continuous 3/0 sutures and anchored to the serosal lined trough formed by the adjacent middle 2 limbs as described by Stein et al. [11]. Afferent limb is covered by mucosa to mucosa, ileal to ileal anastomosis of adjacent middle 2 limbs of the pouch. Ureters are directly anastomosed (stented) to the proximal end of the afferent limb. Grossly dilated ureter was anastomosed by direct end to end and normal caliber ureter by end to side at distal end of afferent limb Closure of anterior wall of pouch into 2 layers and tension-free mucosa to mucosa urethro-ileal anastomosis was performed. The 2 intrapelvic gravity drainage tubes were removed 24 hours after fluid drainage had ceased, while the ureteric stents and urethral catheter were removed at 10,12 and 21 days, respectively (Fig. 1).

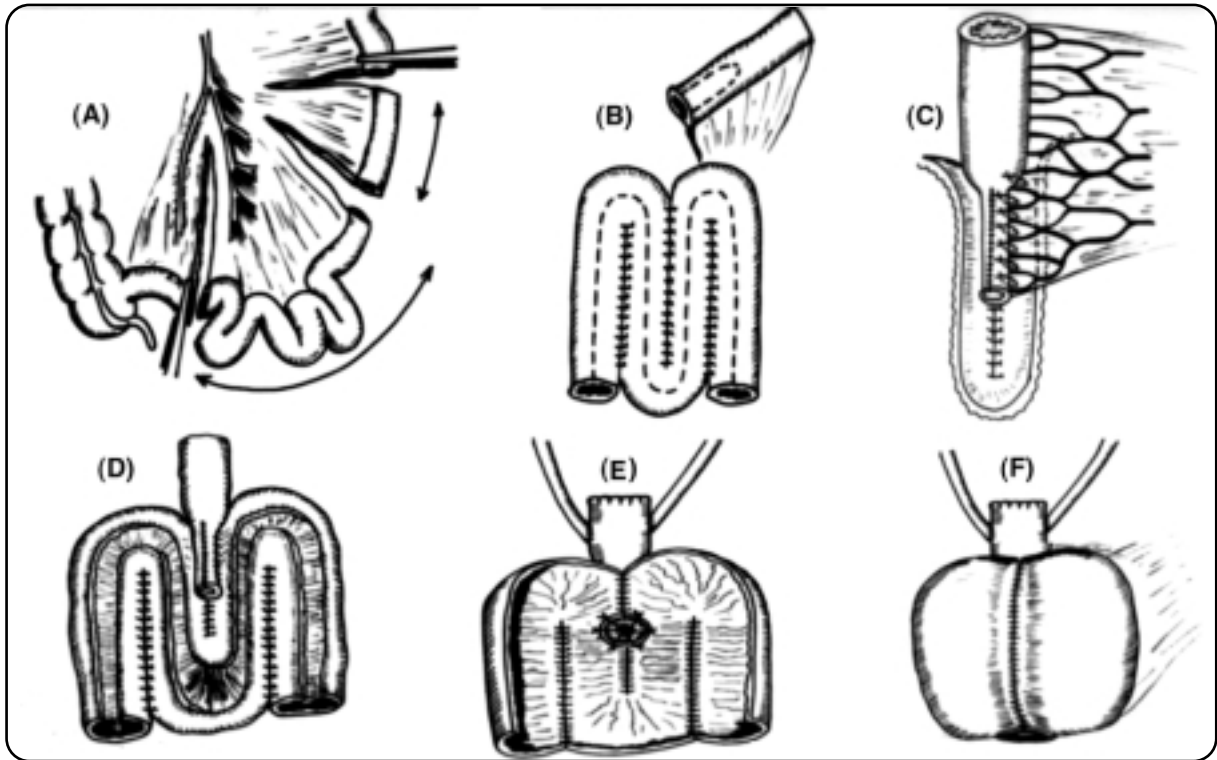
Mean follow up was 24 months (range 18-42). Follow-up included clinical examination, laboratory, radiological and urodynamic investigations. Clinical follow up focused on symptom analysis for continence and voiding pattern, in addition to clinical examination for evidence of local recurrence or distant metastasis. Complete continence was defined as no urinary leakage and no use of protective pads, while satisfactory continence was defined as occasional need for pads, while incontinence was continuous need for protective pads. Radiological investigations included serial abdominal ultrasound (US), gravity pouchography after 6 months, excretory urography (IVP) after 12 months, computed tomography (CT) for abdomen and pelvis in suspected cases of local and/or distant tumor progression. Urodynamic investigations included pouchometry and uroflowmetry for 20 continent cases after 12 months. Significant residual urine is defined as  $>$  20% of pouch capacity.

## RESULTS

Operative time for construction of pouch ranged from 2-3 hours, in addition to the time of radical cystectomy. Early postoperative complications were recorded in 3 cases (prolonged ileus in 1, urinary leakage in 1 associated with wound infection in 1 out of 2 patients), that were managed conservatively.

Data of incontinence after modified T pouch is summarized in table (1) according to its time (whether diurnal or nocturnal) and per individual. All patients voided by Valsava maneuver with relaxation of the pelvic floor muscles. No recorded cases of difficult voiding or need for CIC.

Radiological studies detected that upper urinary tracts remain unchanged or improved with no evidence of reflux in all cases (Fig. 2-A,B & C), with no difference between normal caliber and dilated ureters. No significant residual urine was recorded. Mean post void residual urine was 30 (0-60) ml. Maximum capacity ranged between 480-670 (mean 600 ml). Mean pressure at maximum capacity was 17cm H<sub>2</sub>O (range 15-19). Mean flow rate was 17.6ml/sec (range 15-24). Pelvic cancer recurrence was recorded in 5 patients with distant metastasis in 2 patients at mean 24 months (range 22-40), respectively.



Legends

- Fig. (1-A): Modified T pouch is constructed from 48cm of distal ileum which is divided into distal 40cm and proximal 8cm segments, each with a separate mesentery.
- Fig. (1-B): Distal segment is configured into M shape with 4 equal limbs each is 10cm length. Adjacent limbs are approximated by 3/0 interrupted seromuscular silk sutures. Proximal 8cm segment is used as an afferent limb.
- Fig. (1-C): Lateral view of afferent limb.
- Fig. (1-D): Antimesenteric border is incised by diathermy knife. Mucosa of adjacent limbs are approximated by continuous 3/0 polyglycolic sutures Distal 4 cm of afferent limb is tailored over a 30 Fr. catheter, closed by one layer continuous 3/0 polyglycolic sutures and anchored to the serosal lined trough. afferent limb is moved to the trough formed by the adjacent middle 2 limbs.
- Fig. (1-E): Afferent limb is covered by mucosa to mucosa, ileal to ileal anastomosis of adjacent middle 2 limbs of the pouch. Ureters are directly anastomosed to the proximal end of the afferent limb.
- Fig. (1-F): Closure of anterior wall of pouch into 2 layers. Most dependant part of pouch is ready for urethral anastomosis.

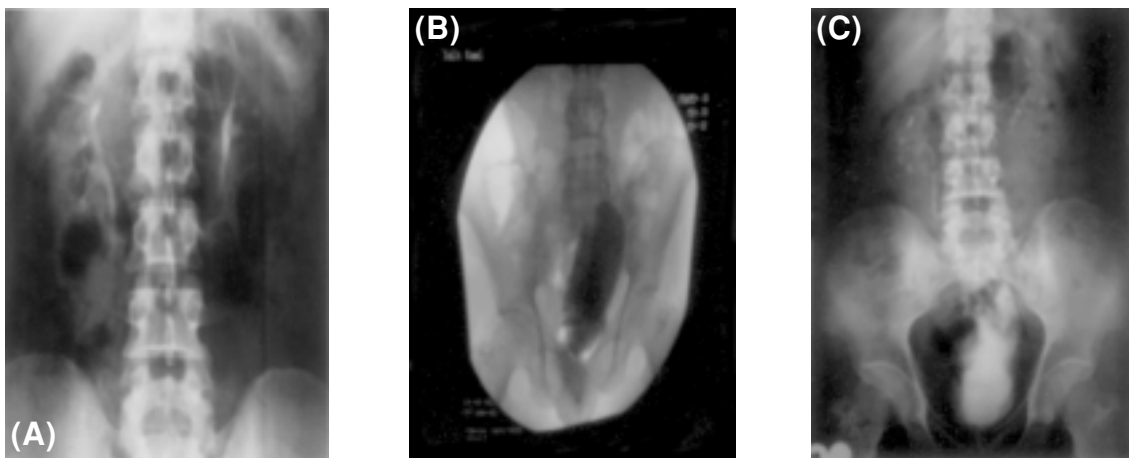


Fig. (2): A, Preoperative IVP. FIG2 B, follow up pouchography 6 months after surgery demonstrates good capacity of the pouch with no reflux at maximum capacity. FIG2 C, IVP 2 years after surgery shows preservation of upper urinary tract.

Table (1): Continence data in relation to time and individual.

Continence data	No. Pts Total=42	(%)
<i>I- Continence per individual:</i>		
Continent day and night.	29	69
Continent day and satisfactory night.	5	11.9
Satisfactory day and night.	6	14.3
Satisfactory day and enuretic at night.	2	4.8
<i>II- Diurnal or Nocturnal result:</i>		
<i>a- Day continence:</i>		
Complete day continence.	34	81
Satisfactory day continence.	8	19
<i>b- Night continence:</i>		
Complete night continence.	29	69
Satisfactory night continence.	11	26.2
Nocturnal enuresis.	2	4.8

## DISCUSSION

Orthotopic ileal neobladder is an appealing method of urinary diversion. Operative and early postoperative complications are strongly affected by proper selection of patients, anesthetic procedure, refined surgical skills and postoperative care. Use of antireflux in case of low pressure reservoir is a matter of debate [16], however we and others [6,11,17] believe that unidirectional antireflux ureteroileal anastomosis is an important issue. Grossly dilated and compromised ureteral length by pelvic irradiation or tumor involvement are two real limitations of serosal lined ureteral tunnel antireflux technique [6] incorporated with ileal neobladder. [11]. Dilated ureters and pathologically affected ureters are common bilharzial sequelae [18]. Too short ileal mesentery is not infrequently encountered and it can limit ileal pouch mobilization to have tension free urethro-ileal anastomosis [8-10]. Both modifications of W-shaped ileal neobladder and surgical tricks [7] to overcome those limitations are a matter of debate among authors [8-10]. Interposition of a segment or tailoring of the pouch at point of urethro-pouch anastomosis may provide tension free urethro-pouch anastomosis. However, this can interfere with the dynamics of ileal neobladder orthotopic reservoir evacuation, voiding and continence [2,7]. Our functional results in terms of continence, preservation of UUT and urodynamics are favorably comparable with early

reports of the T pouch [11,19]. Complete day and night continence were 81% & 69%, while they were 75% & 65% [11] and 83% & 89% [19], respectively by others. In the mean while, results of T pouch are favorably comparable with other series of ileal neobladder reservoirs [1,2,6,19-21]. Differences in continence rate may be due to the bias in different definitions of continence and its link to time and not per individualized patient like we reported, which is the most important parameter for success. Some considered that use of a single pad at night is a good result [22,23]. No reported cases of significant residual urine or CIC [11,19] due to outflow obstruction, while that was reported in other series of ileal neobladders [6,22-24]. Radiological evaluations confirmed a good pouch capacity with no evidence of anastomotic strictures or deterioration of UUT [11,19]. Reflux was not reported in our series (0/42) like others(0/40) [11], while it was recorded in 1/72 [19] cases in T pouch series.

Advantages of T- pouch included stable antireflux mechanism through its fixation of afferent limb by vascular arcades within serosal trough of the ileal pouch, accommodation of short (up to renal pelvis) [11] and dilated ureters, in addition to tension free urethro-ileal anastomosis. Also, it avoids the complications associated with intussuscepted afferent limb and stone formation over the metallic staples [15,17,22]. We think that our modification maximize the postulated advantages of T pouch, it requires shorter segment of ileum (6 cm less) and adds simplicity for a construction of the pouch, through M shape reconfiguration with 4 equal limbs 10 cm in length and dependant predetermined site without need for final folding of pouch to create urethro-pouch anastomosis. Also it incorporated options for both grossly dilated and short ureters. Grossly dilated ureter is anastomosed by direct end to end and normal caliber ureter by end to side at distal end of afferent limb.

### Conclusions:

Modified T pouch has an excellent functional criteria as an orthotopic ileal neobladder reservoir. It is absolutely indicated in short or massively dilated ureter. It is a versatile technique that added simplicity to the original one. Long term results and much larger series are requested.

## REFERENCES

- 1- Hautmann R.E., Egghart G., Frohneberg D. and Miller M.: The ileal neobladder J. Uol., 1988, 139: 39-42.
- 2- Studer U.E., Ackerman W., Aragona F., et al.: Three years experience with an ileal low pressure bladder substitute. Br. J. Urol., 1989, 63: 43-52.
- 3- Abol-Enein H. and Ghoneim M.A.: A novel uretero-ileal reimplantation technique: The serous lined extramural tunnel. A preliminary report. J. Urol., 1994, 151: 1193-1197.
- 4- Hollowell C., Christiano A. and Steinberg G.: Technique of Hautman ileal neobladder with chimney modification: interim results in 50 patients. J. Urol., 2000, 163: 47-50.
- 5- Parekh D., Gilbert W.B. and Smith J.Jr.: Functional lower urinary tract voiding outcomes after cystectomy and orthotopic neobladder. J. Urol., 2000, 163: 56-58.
- 6- Abol-Enein H. and Ghoneim M.A.: Functional results of orthotopic ileal neobladder with serous-lined extramural ureteral reimplantation: Experience with 450 patients. J. Urol., 2001, 165: 1427-1432.
- 7- Abol-Enein H.: Editorial comment. Egyptian Journal of Urology, 2001, Vol. 8: No. 1: 14.
- 8- Zaazaa M.A. and El-Zaher M.A.: Urethroileal anastomosis in W-neobladder: A new technique. 34th Annual Congress of the Egyptian Urological Association; Aswan, Egypt. November, 7-12, 1999: Abstract p. 38.
- 9- Sadek S.Z.: Modified urethra-ileal anastomosis in orthotopic W-Shaped neobladder. Egyptian Journal of Urology, 2001, Vol. 8. No. 1: 14.
- 10- Hammouda H.M.: M-neobladder with intact tail (Hammouda technique). Preliminary results of a novel technique 35 th Annual Congress of the Egyptian Urological Association, Cairo, Egypt. November, 13-17, 2000: Abstract p. 61.
- 11- Stein J.P., Lieskovsky G., Ginsberg D.A., Bochner B.H. and Skinner D.G.: The T. Pouch: an orthotopic ileal neobladder incorporating a serosal lined ileal antireflux technique. J. Urol., 1998, 159: 1836-1842.
- 12- Bissada N.K.: Continent cutaneous diversion using the ileocecal segment, In Crawford E.D., and Das S (Eds): Current Genitourinary Cancer Surgery, 2<sup>nd</sup> E.D. Philadelphia, Lea & Fabiger, 1995, pp 414-425.
- 13- Hammouda H.M.: Charleston pouch with insitu appendix and concealed umbilical stoma. African Journal of Urology, 2003, 9: 177.
- 14- Skinner D.G. and Lieskovsky G.: Technique of radical cystectomy. In: Diagnosis and Management of Genitourinary Cancer. Edited by D.G. Skinner and G. Lieskovsky. Philadelphia: W.B. Saunders. 1988, chapt. 42, pp.607-621.
- 15- Elmajian D.A., Stein J.P., Esrig D., Freeman J.A., Skinner E.C., Boyd S.D., Lieskovsky G. and Skinner D.G.: The kock ileal neobladder : updated experience in 295 male patients. J. Urol., 1996, 156: 920-925.
- 16- Allan J.P., Ken-Ryu H., Michael P., Robert E.W., et al.: ureteroenteric anastomosis in continent urinary diversion: Long term results and complications of direct versus non refluxing techniques. J. Urol., 2000, 163: 450-455.
- 17- Stein J.P., Freeman J.A., Esrig D., Elmajian A., Tarter T.H., Skinner E.C., Boyd S.D., Huffman J.L., Lieskovsky G. and Skinner D.G.: Complications of the afferent antireflux valve mechanism in the kock ileal reservoir. J. Urol., 1996, 155: 1579-1584.
- 18- Smith J.H. and Christie J.D.: The Pathobiology of Schistosoma haematobium infection in humans. Human Pathology, 1986, 17: 333-345.
- 19- Stenzl A.: T-Pouch diversion shows good capacity, little reflux. Urology Times, 2000, 25 (6): 28.
- 20- Pagano F., Artibani W., Aragona F., et. al.: Vesica ileal padvana (VIP): surgical technique, long term functional evaluation, complications and management. Arch Esp Urol., 1997, 50: 785.
- 21- El-Bahnasawy M.S., Osman Y. and Shaaban A.A.: The urodynamic features of orthotopic ileal reservoir: A comparison between hemi-Kock pouch and W neobladder. African Journal of Urology, 2001, Vol. 7, No. 2: 66.
- 22- Elmajian D.A., Stein J.P., Esrig D., Freeman J.A., Skinner E.C., Boyd S.D., Lieskovsky G. and Skinner D.G.: The kock ileal neobladder: updated experience in 295 male patients. J. Urol., 1996, 156: 920-925.
- 23- Hautmann R.E., De Petriconi R., Gottfried H.W. et al.: The ileal neobladder: complications and functional results in 363 patients after 11 years of follow-up. J. Uol., 1999, 161: 422-427.
- 24- Steven K. and Poulson A.L.: The orthotopic kock ileal neobladder: functional results urodynamic features, complications and survival in 166 men. J. Urol., 2000, 164: 288-295.