

## The Use of Tensor Fascia Lata Pedicled Flap in Reconstructing Full Thickness Abdominal Wall Defects and Groin Defects Following Tumor Ablation

MOHAMAD A. RIFAAT, M.D., F.R.C.S. and WAEL SAMI ABDEL GAWAD, M.D., F.R.C.S.

*The Department of Surgical Oncology, National Cancer Institute, Cairo University.*

### ABSTRACT

**Background:** The tensor fascia lata is a versatile flap with many uses in reconstructive plastic surgery. As a pedicled flap its reach to the lower abdomen and groin made it an attractive option for reconstructing soft tissue defects after tumor ablation. However, debate exists on the safe dimension of the flap, as distal tip necrosis is common. Also, the adequacy of the fascia lata as a sole substitute for abdominal wall muscles has been disputable. The aim of the current study is to report our experience and clinical observations with this flap in reconstructing those challenging defects and to discuss the possible options to minimize the latter disputable issues.

**Patients and Methods:** From April 2001 to April 2004, 12 pedicled TFL flaps were used to reconstruct 5 central abdominal wall full thickness defects and 6 groin soft tissue defects following tumor resection. In one case, bilateral flaps were used to reconstruct a large central abdominal wall defect. There were 4 males and 7 females. Their age ranged from 19 to 60. From the abdominal wall defects group, all repairs were enforced primarily with a prolene mesh except for one patient who was the first in this study. Patients presenting with groin defects required coverage of exposed vessels following tumor resection. All patients in the current study underwent immediate reconstruction.

**Results:** The resulting soft tissue defects in this study were due to resection of 4 abdominal wall desmoid tumors, a colonic carcinoma infiltrating the abdominal wall, 4 primary groin soft tissue sarcomas, a metastatic SCC of the leg to groin nodes, and a primary SCC of the groin.

The size of the flaps used ranged from 20x10cm to 31x18cm. All flaps survived. However, distal flap necrosis occurred in 4 cases. Three of those cases developed in flaps reconstructing abdominal wall defects, and one case developed in a flap used to cover a groin defect. In the former 3 cases, the flap was simply transposed without complete islanding of the flap. In the latter case, a very large flap was harvested beyond the safe limits with its distal edge just above the knee. In addition, wound dehiscence of the flap occurred in 2 other cases from the groin

group. Nevertheless, all the wounds healed spontaneously with repeated dressings. Out of the 5 cases that underwent abdominal wall reconstruction, one case developed ventral hernia, in which bilateral TFL flaps were used without mesh enforcement. There was minimal donor site morbidity in the form of partial skin graft loss in 2 cases. The average follow up period in this study ranged from 6 months to 2 years. Only one patient died of distant metastasis of a SCC of the groin skin, 8 months postoperatively and another 2 patients with abdominal desmoid tumors developed local recurrence.

**Conclusion:** The tensor fascia lata flap is a reliable and a versatile flap, with minimal donor site morbidity. Problems with the flap's vascularity of its distal part should not be encountered, if the flap is harvested within the safe limits and properly designed and the edges comfortably insetted to the defect. A pedicled flap would be appropriate for lower abdominal wall defects, and is better islanded to achieve extra mobilization and allow a tension free closure, while for groin defects, simple flap transposition should be enough. Nevertheless, reconstruction for full thickness abdominal wall defects by this flap is a static reconstruction. We therefore strongly recommend enforcing the repair with a synthetic mesh primarily to minimize the incidence of ventral hernia. However, further studies with larger number of cases are needed to confirm this observation.

**Key Words:** *Tensor fascia lata - Abdominal wall reconstruction - Groin reconstruction.*

### INTRODUCTION

Tensor fascia lata flap is a myofasciocutaneous flap that has been first described by Wangenstein in 1934 for abdominal wall reconstruction [1]. This flap started to gain popularity after further description by Nahai, et al., 1978 and 1979 [2,3].

The tensor fascia lata flap (TFL) is a versatile flap with many applications in Plastic Surgery.

It has a significant role in the management of pressure sores [4], facial reanimation [5]. Also, it has been used as a free flap in head and Neck reconstruction [6]. As a pedicled flap, with a strong fascial layer, its reach to the lower abdomen and the groin made it an attractive option for reconstruction of these challenging defects.

In dealing with the management of soft tissue tumors of those anatomical regions, highly aggressive local resection is required to achieve optimal local treatment and minimize recurrence [7,8]. This is usually attained with massive soft tissue loss and exposure of vital structures and therefore, there is a need for immediate reconstruction. However, distal necrosis of the tensor fascia lata flap whether pedicled or free has been commonly reported and controversy exists on the flap's safe dimensions to minimize such problem [9,10,11].

The adequacy of the fascial component of the flap for a sound abdominal wall reconstruction has been another controversial issue [12,13].

In the present study, 12 pedicled TFL flaps were used to reconstruct full thickness abdominal wall and groin defects following tumor resection. Our experience with this flap and our view on its controversial issues are presented.

## PATIENTS AND METHODS

Over a period of 3 years, from April 2001 to April 2004, 12 pedicled TFL flaps were used to reconstruct 5 central abdominal wall full thickness defects and 6 groin soft tissue defects following tumor resection. In one case, bilateral flaps were used to reconstruct a large central abdominal wall defect involving supra and infraumbilical regions. All patients underwent primary reconstruction. There were 4 males and 7 females. Their age ranged from 19 to 60. The demographic data of patients, site of the defect, pathology of underlying disease, and the size of the flaps are summarized in table (1). All repairs of abdominal wall defects were enforced primarily with a prolene mesh except for one patient [case 3 (Table 1-A)], who was the first patient in this study. All patients presenting with groin defects required coverage of exposed vessels following tumor resection and to enhance primary wound healing in this area notorious for slow healing.

### Technique:

The technique of harvesting of TFL is described elsewhere [2,3,14]. However, herein is a brief summary. The flap was outlined on the thigh according to the desired size. The site of the pedicle (the transverse branch of the lateral circumflex femoral artery) was also marked, which is about 8-10cm below the anterior superior iliac spine. A skin island up to 15cm in width was reliably elevated in that zone from the pedicle site to around 8cm above the knee. The anterior incision started medially, and was deepened down to fascia. The elevation was carried out in a subfascial plane from distal to proximal.

The lateral circumflex femoris artery was then easily identified high up as it passes between the rectus femoris and the vastus lateralis, where it gives the transverse branch, which pierces the TFL muscle accompanied by venae comitantes. This vessel sends perforators to the overlying skin. The motor nerve supply of the muscle is via the superior gluteal nerve, which enters the posterior surface of the muscle.

The sensory supply is by the lateral cutaneous branch of T12, and the lateral femoral cutaneous nerve of the thigh. Dissection then continued, and the skin and fascia were divided all around if more mobilization was necessary. If the flap was used to cover the groin, the latter step was not needed, as the defect would be in close proximity to the flap, and a bridge of the skin, muscle and the fascia incorporating the pedicle were left just enough to allow for simple rotation of the flap. If further mobilization of the flap or lengthening of the pedicle was required, the muscle branches of the lateral circumflex femoral artery were divided and the flap was completely islanded to allow rotation 180 degrees. Donor site was then closed directly if the width was less than 9cm; otherwise a split skin graft was applied.

## RESULTS

The size of the flaps used ranged from 20x10cm to 31x18cm. All flaps survived. However, distal flap necrosis occurred in 4 cases. In three cases, the flap was used for abdominal wall reconstruction. In 2 of these cases, the defects were abutting the umbilical region. The defect in the third case was infraumbilical. The flap in the latter 3 cases was simply transposed

to the defect, while leaving the bridge of skin of the proximal part attached. The wounds were treated with repeated dressings after debridement of the necrotic area and all healed spontaneously. In the fourth case, a very large flap was harvested; with its distal end only few centimeters away from the knee to cover a groin defect involving the lower abdomen, and again, the necrotic area was debrided and the wound healed spontaneously. Wound dehiscence of the flap occurred in another two cases where the flap

was used to reconstruct groin defects. This was also treated conservatively, and wounds healed spontaneously.

Out of the 5 cases that underwent abdominal wall reconstruction, one case developed ventral hernia [case-3 (Table 1)] in which bilateral TFL flaps were used without mesh enforcement. There was no hernia reported in the remaining 4 patients. Only, one case from the latter group developed slight bulging of abdominal wall without further consequences.

Table (1-A): Abdominal wall reconstruction.

| Case no. | Age | M/F | Pathology  | Site of defect                           | Mesh/Flap laterality & size                 | Complication   | Disease Outcome                      |
|----------|-----|-----|--|--|---|--|--------------------------------------|
| 1        | 50  | F   | Desmoid tumor infiltrating sigmoid colon                 | Infraumbilical                           | Yes/Unilateral- 27x12cm                     | Slight abdominal bulging & distal tip necrosis, healed spontaneously | No evidence of disease for 2-years   |
| 2        | 60  | F   | Desmoid tumor  | Infraumbilical                           | Yes/Unilateral- 31x18cm                     | Distal tip necrosis, healed spontaneously                            | Local recurrence after one year      |
| 3        | 45  | F   | Desmoid tumor  | Central abdomen (supra & infraumbilical) | No/Bilateral TFL island flaps- 30x11cm each | Ventral hernia (treated with 2ry mesh)                               | Local recurrence after 2 years       |
| 4        | 56  | F   | Recurrent carcinoma of colon infiltrating abdominal wall | Infraumbilical                           | Yes/Unilateral- 24x12cm                     | Distal tip necrosis, healed spontaneously                            | No evidence of disease for 18 months |
| 5        | 45  | F   | Desmoid tumor  | Infraumbilical                           | Yes/Unilateral- 25x10cm                     | None   | No evidence of disease for 1-year    |

Table (1-B): Groin reconstruction.

| Case no. | Age | M/F | Pathology   | Flap laterality & size | Complication                            | Disease Outcome                           |
|----------|-----|-----|---|------------------------|---|---|
| 1        | 30  | M   | SCC of left leg (marjolin ulcer) with fungating nodes of right groin      | Unilateral/10x20cm     | None                                    | Died of distant metastasis after one year |
| 2        | 40  | M   | Recurrent dermatofibrosarcoma of left groin                               | Unilateral/21x12cm     | None                                    | No evidence of disease for one year       |
| 3        | 19  | M   | Recurrent peripheral neuroectodermal tumor of right groin                 | Unilateral 23x10cm     | None                                    | No evidence of disease for 18 months      |
| 4        | 50  | F   | Myxoliposarcoma of right groin  | Unilateral 20x11cm     | Wound dehiscence (healed spontaneously) | No evidence of disease for one year       |
| 5        | 35  | F   | Incompletely excised Malignant fibrous histiocytoma, of left groin        | Unilateral 22x12cm     | Wound dehiscence (healed spontaneously) | No evidence of disease for 8 months       |
| 6        | 55  | M   | Recurrent fungating multiple SCCs of Right Groin and lower abdominal skin | Unilateral 31x15cm     | Distal tip necrosis                     | No evidence of disease for 6 months       |

Sec: Squamous cell carcinoma.

TEL: Tensor fascia lata.

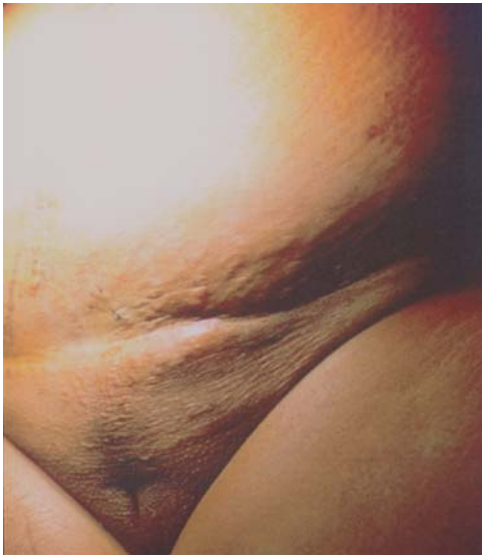

Fig. (1-A): [Case 1 (Table 1-A)], showing preoperative view of desmoid tumor of infraumbilical region.

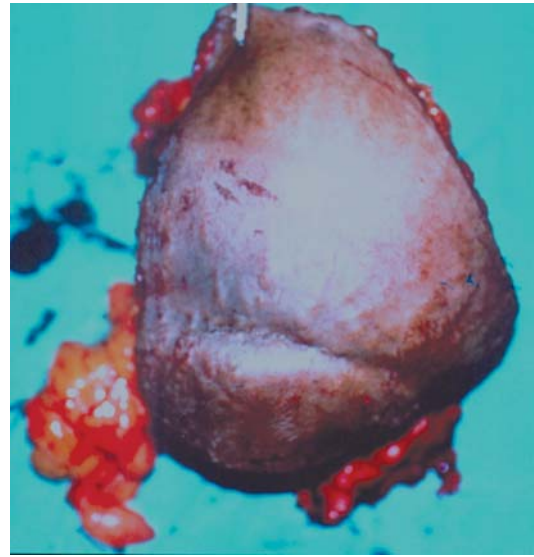


Fig. (1-B): Showing resected specimen including the tumor, overlying muscles and skin, and the sigmoid colon.

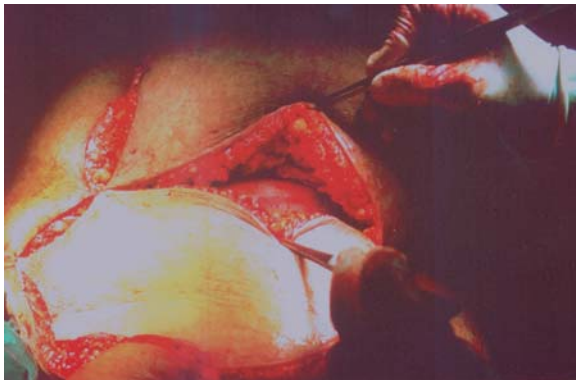

Fig. (1-C): Showing the flap being rotated over the defect. Note, the prolene mesh having been applied over the omentum before the flap.

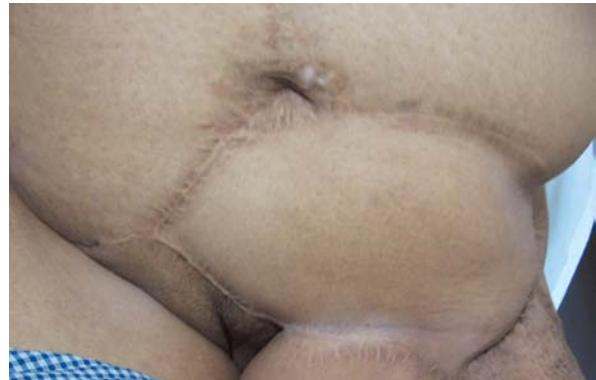

Fig. (1-D): Showing a 2-year postoperative view of the flap lying on top of prolene mesh covering the infraumbilical defect in Fig. (1-C). Note slight abdominal bulging at the flap site, and skin graft scar over the donor site.

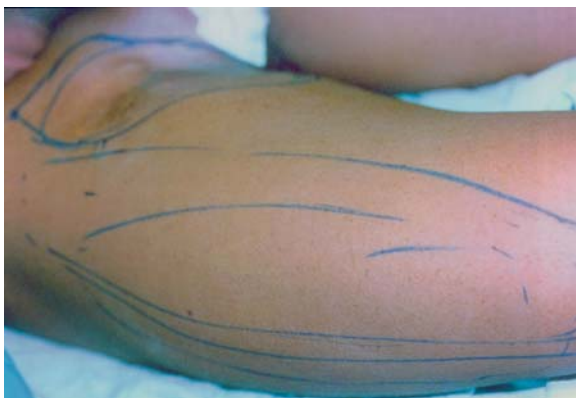

Fig. (2-A): [Case 3 (Table 1-B)], showing a preoperative view of recurrent peripheral neuroectodermal tumor of the right groin. Note, marking of the TFL flap on the thigh.

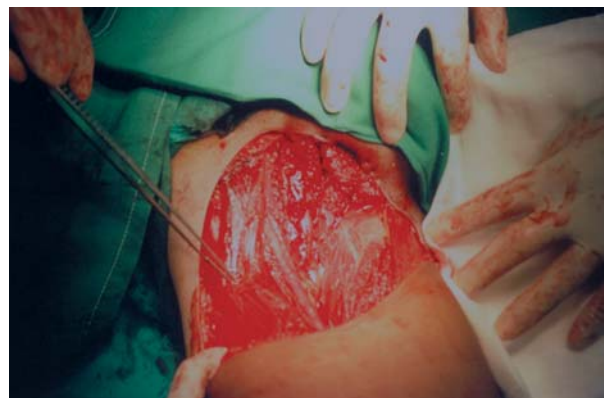

Fig. (2-B): Showing groin defect with exposed femoral vessels following tumor resection in Fig. (2-A).

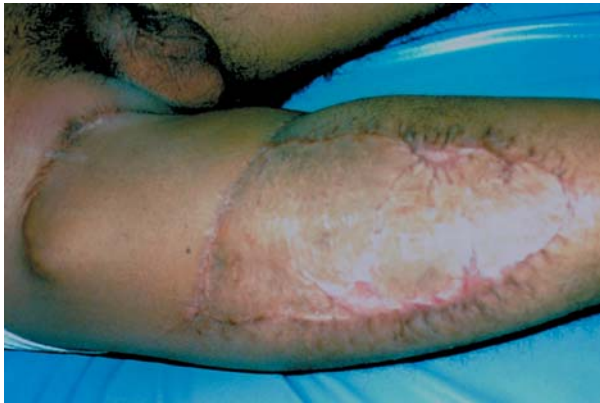

Fig. (2-C): Showing one year postoperative view of the TFL flap covering the groin defect. Note, the skin graft covering the donor site defect.

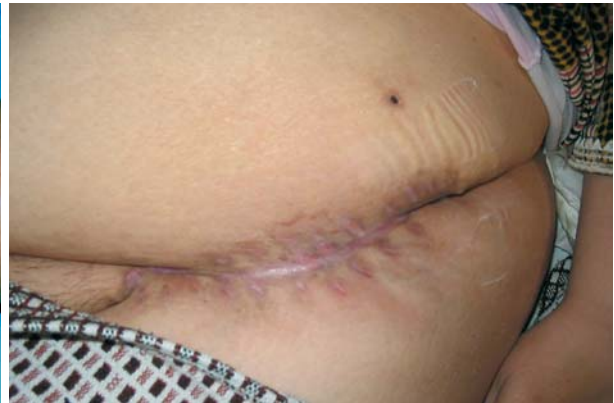

Fig. (3-A): [Case 5 (Table 1-B)], showing preoperative view of a scar resulting after incomplete removal of malignant fibrous histiocytoma of left groin.

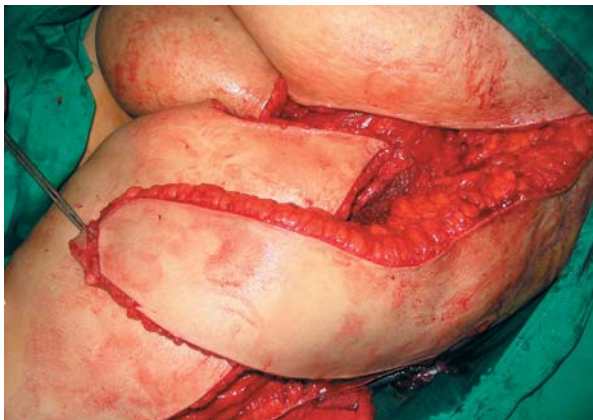

Fig. (3-B): Showing the defect resulting after wider excision of the scar and the flap being rotated.

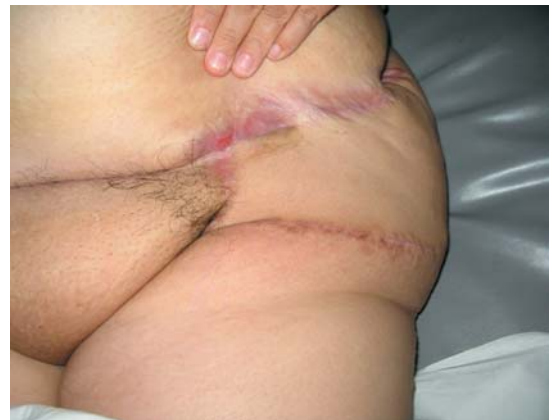

Fig. (3-C): Showing 8 months postoperative view of the flap settling well over the defect.

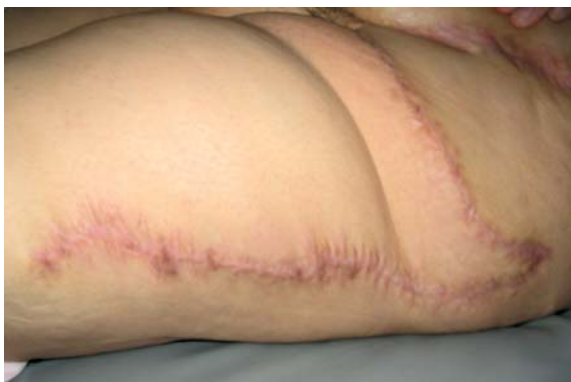

Fig. (3-D): Showing 8 months postoperative view of donor site scar healed by primary intention after primary closure.

As regards the donor site, all wounds were closed with a split skin graft apart from one case, which was closed primarily. There were

no reported donor site complications apart from partial skin graft loss in two cases, which healed spontaneously. Also, there was no clinically detectable functional morbidity in the form of knee instability or gait disturbances in any of the cases in this study.

The average follow up period ranged from 6 months to 2 years. One patient developed distant metastasis of a SCC of the groin skin and died of his disease 8 months later. Another 2 patients with abdominal desmoid tumors developed local recurrence under the flap at one and two years postoperatively, and both underwent adequate excision with safety margin and closure utilizing the residual skin flap and fascia with mesh support. The remaining patients in this study showed no evidence of disease until the end of the 2-year follow up period (Table 1A, 1B).

## DISCUSSION

The need for adequate resection of soft tissue tumors of the groin to achieve local tumor control is usually attained with a high wound complication rate, reaching up to 40-60%. Those wounds are known for slow healing, with frequent exposure of vital structures like femoral vessels [15,16,17]. Nevertheless, wound problems may still occur with minimal skin excision or even following simple elevation of skin flaps for groin dissection, to the extent that some authors advocated the use of routine prophylactic flaps in an attempt to minimize these problems [18,19].

Several flaps have been described to cover established groin defects; each has its own advantages and disadvantages. Inferiorly based rectus abdominis muscle or myocutaneous flap has been used [17,20]. Other flaps such as rectus femoris, sartorius with abdominal skin flap, internal oblique muscle flap and vastus lateralis flaps have been also described [2,21,22,23]. However, those flaps are not without complications or morbidities. Abdominal weakness, bulging or hernia may follow the use of rectus abdominis flap [23]. Rectus femoris muscle flap may cause significant knee weakness [24]. Internal oblique muscle is small, and dissection can be bloody and tedious [21].

Alternatively, the tensor fascia lata flap (TFL) has been advocated for coverage of groin defects by many authors with great success with relatively lower donor site morbidity, compared to other flaps [25,26]. In the current study, the flap was easily harvested, in close proximity to the defect and rotated to the groin area, and successfully covered all the defects. Wound dehiscence of the flap has only occurred in 2 cases. The latter complication has been reported in one study to occur in 30% of cases [11]. There is no explanation to the reason for this complication. However, we believe this problem may occur when the recipient bed is potentially infected (e.g. fungating tumor). Nevertheless, in the present study, with repeated dressings, eventually, the wound has spontaneously healed.

As regards to defects of abdominal wall, they may arise following resection of primary soft tissue tumors or secondary tumors directly invading abdominal wall. In this anatomical region, desmoid tumors are the commonest

primary soft tissue tumors (47%), followed by dermatofibrosarcoma protuberance (24%) and then soft tissue sarcomas. The treatment approach of all these three diseases again remains to be complete resection to achieve adequate local control, and hence immediate reconstruction of the resulting composite defect and protection of the exposed viscera is essential [8].

Desmoid tumor was the commonest tumor in the present study. Needless to say, the ideal reconstruction of abdominal wall should provide a tension free repair and dynamic muscle support if possible. If the skin is adequate, a prosthetic mesh, or alternatively, an autologous fascial substitute may be used. On the other hand, if skin is inadequate, the resulting full thickness defect will require a cutaneous or a myocutaneous flap with or without a synthetic mesh, depending on the adequacy and the availability of a fascial substitute to provide strength to the abdominal wall [27,28].

Autologous tissue may involve the use of local or distant flaps. A local flap such as rectus abdominis flap, may be superiorly or inferiorly based, for upper or lower lateral defects, respectively [29]. Gradual tissue expansion of abdominal muscles over weeks [30], and components separation technique, which entails medial mobilization of intact muscles of abdominal wall, while retaining their neurovascular supply to close midline defects, have been also described [31].

However, the latter methods may not be suitable in the field of surgical oncology, due to either resection of the residual muscles, or the length of time required for tissue expansion [32]. Although artificial materials used for abdominal wall reconstruction has demonstrated increased complication rate, a synthetic mesh such as a prolene mesh, if properly applied with a barrier between it and the gut such as the omentum, or if applied extraperitoneally, complications are kept to a minimum [33,34,35].

If a prolene mesh is not appropriate to use, either because of infection or absence of omentum, a strong fascial layer from a distant area like the fascia lata of the thigh can be alternatively utilized [36]. After the work of Nahai et al. [2,3] on the tensor fascia lata musculofascial flap for abdominal wall reconstruction, the method became popular and was reported by

other authors [10,11,26,37,38,39]. There is a general agreement to use a single free TFL flap, which is easily and freely oriented in a transverse manner to reconstruct a high supraumbilical defect; instead of bilateral pedicled vertically oriented flaps [10,11,37,40,41].

In the current study, while we were developing our experience with microsurgery, we used a bilateral vertically oriented TFL flaps [case (3) Table 1], avoiding a free tissue transfer. The main disadvantage was the additional increase in donor site morbidity provided by another flap.

Other pedicled flaps from the thigh such as extended rectus femoris, with or without tensor fascia lata, and anterolateral thigh flap have been also described [40,42]. The rectus femoris muscle flap, although is claimed to provide a dynamic reconstruction to the repair, it may be complicated with some weakness of knee extension [24,42]. Furthermore, the TFL flap dissection is relatively easy compared to the anterolateral thigh flap.

The advantage of the TFL flap is the provision of a well vascularized tissue composed of skin, subcutaneous tissue muscle and fascia, that can be used in an irradiated field. In addition, the flap has lower donor site morbidity, and the muscle itself is dispensable and its absence usually causes no remarkable functional deficit or knee instability [10,14,23,38,43]. In the current study, only 2 patients developed partial skin graft loss on their donor sites. Both wounds healed spontaneously with no further problems.

However, the two major disputes on the TFL flap are firstly, the effectiveness of the fascia lata as a strong fascial substitute for abdominal wall integrity preventing the development of ventral hernia and secondly, the identification of the safe dimension of the flap, whether it is used as a pedicled or as a free flap to reconstruct any particular defect.

In so far as abdominal wall reconstruction is concerned, some authors consider that the fascia lata is solely an effective tissue that negates the use of a mesh with its potential complications, and with a low incidence of a recurrent hernia [10,26,44,45]. Indeed, other authors claimed that as the flap is transferred with its intact motor nerve supply to the muscle, a

dynamic reconstruction is achieved as the muscle retains its tone, which is transmitted to the fascia, making it an ideal method for abdominal wall reconstruction [2,3].

Shestak et al. [13], and Koshima et al. [46] challenged the latter statement and found that musculocutaneous or musculofascial pedicled flaps such as TFL are usually denervated with subsequent atrophy of muscle component. In addition, they are too thin to tolerate high abdominal pressure, with a predictable occurrence of tissue laxity. Hence, recurrent abdominal wall protrusion or hernia is likely to occur. The latter authors believed that a microsurgical free enervated rectus femoris muscle flap, combined with TFL flap should provide a dynamic physiological reconstruction to the abdominal wall, with no hernia recurrence.

However, further studies are required to assess the long-term results of such a complicated transfer. Furthermore, Carlson et al. [12] reported that the recurrence rate for herniation after repair with the TFL flap was quite high (42%) and for the same reason, Shestak et al. [13] advocated reinforcement of the initial autogenous repair with a synthetic mesh. It is worth to mention that regardless the type of the repair, whether dynamic or static, ventral hernia can still occur. There are other factors that may predispose to hernia recurrence such as obesity, chronic obstructive airway disease, malnutrition, anemia, sepsis, postoperative weight gain, and concurrent malignant process [13,35,44,47].

In the present study, case-3 (Table 1) presenting with a large abdominal wall defect involving both supra and infra umbilical regions, a bilateral islanded TFL flaps were done without mesh reinforcement. This was the first case in this study. Although the flaps successfully covered the defect without wound problems, the patient then developed hernia 6 months later, and a secondary repair of the hernia was then done with a prolene mesh.

The remaining 4 patients, presenting with abdominal defects in this study, had a high body mass index, and a synthetic (prolene) mesh to reinforce the repair was primarily used for all of them. Only, one case from the latter group developed abdominal bulging with no further consequences, but no hernia was reported. The prolene mesh used in those cases was applied

over the omentum, and then covered by the flap. There were no reported problems with the mesh use, in the form of infection, extrusion or intestinal fistula formation. Our results compare favorably with Mathes et al. [36] in which the combined use of mesh and flap for full thickness defects in 6 cases has resulted in 0% recurrence herniation rate. We believe that the role of the fascia lata in abdominal wall repair would be providing a composite flap with an additional strength to the repair and a well-vascularized tissue over the mesh.

In so far as the vascularity of the TFL flap is concerned, it is worth to mention, that tip necrosis has been reported both in pedicled and free TFL flap [9,11,48]. Although, Nahai et al. [2] claimed that the flap could be safely made as large as 15x40cm, and could be raised within 5cm from the knee, other authors challenged this, and advocated that the safe limits are within 8 to 10cm of the knee. The last 5cm of the flap tissue above the knee is random and has a variable success rate [2,14,43,49]. To overcome this problem, some authors have advocated augmentation of the blood supply and the flap's dimensions, by pre-expanding the flap. This will simulate delaying the flap with the added advantage of increasing the dimensions, but the procedure of tissue expansion may take weeks/months and again may not be suitable for cancer patients requiring immediate reconstruction [48,50].

In the present study, although the flap was harvested within the safe limits, distal necrosis occurred only in 3 cases presenting with lower abdominal wall defects. In the latter three cases, the skin bridge including the pedicle was left insitu, and the flap was simply rotated. The pedicle was not visualized and dissected, and hence part of the flap was wasted in the bridge. The flap's distal edge was sutured under tension in those cases trying to compensate for some shortness of the flap to reach the furthest part of the defect, due to an error in the flap's design.

On the other hand, in another case [no 3 (Table 1)] where bilateral TFL flaps were raised with safe dimensions, extra mobilization was achieved by islanding both flaps and complete dissection of the pedicle to reach large supraumbilical regions comfortably in a vertical orientation and this allowed a tension free closure. Although, the donor site morbidity due to scar-

ring increased because of using two flaps, and a ventral hernia developed later as previously mentioned, neither of those flaps developed tip necrosis. Sharma et al. [41] reported the same observation. Interestingly, no distal tip necrosis occurred with flaps used to cover groin defects, in this study. Those defects were relatively smaller and in more proximity to the flap's donor site allowing closure without undue tension. Only one case in the latter group has developed this problem, when the safe dimensions of the flap were exceeded trying to cover a large defect including both the groin and the lower abdomen. The problem of distal flap necrosis has been dealt with in this study by repeated dressings with eventual spontaneous healing and without delaying adjuvant therapy. We agreed with Safak et al. [14] about avoiding harvesting the distal 10cm of skin and fascia above the knee.

In conclusion, the TFL flap is a versatile flap with minimal donor site morbidity. The morbidity of this flap, we believe, lies in thigh scarring which is worse if a skin graft is used especially in females. Problems with the flap's vascularity of its distal part should not be encountered, if the flap is harvested within the safe limits, a proper flap's design is well executed, and the edges are comfortably insetted to the defect. The flap is an easy, reliable and an effective method for reconstruction of groin defects after ablative cancer surgery.

Furthermore, the flap provides a large surface area of vascularized tissue, which is useful, for full thickness abdominal wall reconstruction following tumor resection where local options may not be available. A pedicled flap is appropriate for lower abdominal wall defects, and is better islanded to achieve extra mobilization and allow a tension free closure. Whereas a single free flap freely oriented transversely, instead of bilateral vertically oriented pedicled flaps is a good choice for supraumbilical defects. Nevertheless, tensor fascia lata flap reconstruction for full thickness abdominal wall defects is a static reconstruction, which may not tolerate the high intra abdominal pressure or the possible increase in weight that may develop later on. We, therefore, strongly recommend primarily enforcing the repair with a synthetic mesh to minimize the incidence of ventral hernia. However, further studies with larger number of cases are needed to confirm this observation.

## REFERENCES

- 1- Wangenstein OH. Repair of recurrent and difficult hernias and other large defects of the abdominal wall employing the iliotibial tract of fascia lata as a pedicled flap. *Surg Gynecol Obstet.* 1934, 59: 766-80.
- 2- Nahai F, Hill HL, Hester TR. Experiences with the tensor fascia lata flap. *Plast Reconstr Surg.* 1979, 63: 788-99.
- 3- Nahai F, Silvertson JS, Hill HL, Vasconez LO. The tensor fascia lata musculocutaneous flap. *Ann Plast Surg.* 1978, 1: 372-79.
- 4- Siddiqui A, Wiedrich T, Lewis VL, Jr. Tensor fascia lata V-Y retroposition myocutaneous flap: Clinical experience. *Ann Plast Surg.* 1993, 31: 313-17.
- 5- Spector GJ, Matsuba HM, Killeen TE, Griner NR. Fascial pulley: Cross-commisure lip reanimation for inferior division facial nerve paralysis. *Laryngoscope.* 1986, 96: 102-5.
- 6- Endo T, Nakayama Y. Pharyngoesophageal reconstruction: a clinical comparison between free tensor fasciae latae and radial forearm flaps. *J Reconstr Microsurg.* 1997, 13: 93-97.
- 7- Arnold PG, Lovich SF, Pairolero PC. Muscle flaps in irradiated wounds: An account of 100 consecutive cases. *Plast Reconstr Surg.* 1994, 93: 324-27.
- 8- Stojadinovic A, Hoos A, Karpoff HM, Leung DHY, Antonescu CR, Brennan MF, et al. Soft tissue tumors of the abdominal wall; analysis of disease patterns and treatment. *Arch Surg.* 2001, 136: 70-79.
- 9- Penington AJ, Theile DR, Macleod AM, Morrison WA. Free tensor fasciae latae flap reconstruction of defects of the chest and abdominal wall. Selection of recipient vessels. *Scand J Plast Reconstr Hand Surg.* 1996, 30: 299-305.
- 10- Williams JK, Carlson GW, De Chalain T, Howell R.L., Coleman JJ. Role of tensor fasciae latae in abdominal wall reconstruction. *Plast Reconstr Surg.* 1998, 101: 713-18.
- 11- Williams JK, Carlson GW, Howell RL, Wagner JD, Nahai F, Coleman JJ. The tensor fascia lata free flap in abdominal wall reconstruction. *J Reconstr Microsurg.* 1997, 13: 83-91.
- 12- Carlson GW, Hester TR, Coleman JJ. The role of the tensor fasciae latae musculocutaneous flaps in abdominal wall reconstruction. *Plast Surg Forum.* 1988, 11: 151-57.
- 13- Shestak K.C, Edington HJD, Johnson RR. The separation of anatomic components technique for the reconstruction of massive midline abdominal wall defects: Anatomy, surgical technique, applications, and limitations revisited. *Plast Reconstr Surg.* 2000, 105: 731-38.
- 14- Safak T, Klebuc MJA, KeÇik A, Sheneq SM. The subcutaneous pedicle tensor fascia lata flap. *Plast Reconstr Surg.* 1996, 97: 765-74.
- 15- Hill HL, Nahai F, Vasconez L. The tensor fascia lata myocutaneous free flap. *Plast Reconstr Surg.* 1978, 61: 517-22.
- 16- Mack LA, Temple WJ, Dehaas WG, Schachar N, Morris DG, Kurien E. Groin soft tissue tumors – a challenge for local control and reconstruction: A prospective cohort analysis. *J Surg Oncol.* 2004, 86: 147-51.
- 17- Payne WG, Walusimbi MS, Blue ML, Mosiello G, Wright TE, Robson MC. Radiated groin wounds: Pitfalls in reconstruction. *Am Surg.* 2003, 69: 994-97.
- 18- Parkash S. The use of myocutaneous flaps in block dissections of the groin in cases with gross skin involvement. *Br J Plast Surg.* 1982, 35: 413-19.
- 19- Ravi R. Morbidity following groin dissection for penile carcinoma. *Br J Urolog.* 1993, 72: 941-45.
- 20- Bare RL, Assimos DG, McCullough DL, Smith DP, Defranzo AJ, Marks MW. Inguinal lymphadenectomy and primary groin reconstruction using rectus abdominis muscle flaps in patients with penile cancer. *Urology.* 1994, 44: 557-61.
- 21- Ramasastry SS, Futrell JW, Williams SL, Hurwitz DJ. Internal oblique muscle pedicle flap for coverage of a major soft tissue defect of the groin. *Ann Plast Surg.* 1985, 15: 57-60.
- 22- Rayment P, Evans DM. Use of an abdominal rotation flap for inguinal lymph node dissection. *Br J Plast Surg.* 1987, 40: 485-87.
- 23- Russo P, Saldana EF, Yu S, Chaglassian T, Hidalgo DA. Myocutaneous flaps in genitourinary oncology. *J Urolog.* 1994, 151: 920-24.
- 24- Bostwick J, Hill HL, Nahai F. Repairs in the lower abdomen, groin or perineum with myocutaneous or omental flaps. *Plast Reconstr Surg.* 1979, 63: 186-94.
- 25- Gopinath KS, Chandrashekhar M, Kumar MV, Srikant KC. Tensor fasciae latae musculocutaneous flaps to reconstruct skin defects after radical inguinal lymadenectomy. *Br J Plast Surg.* 1988, 41: 366-68.
- 26- Hill HL, Hester R, Nahai F. Covering large groin defects with the tensor fascia lata musculocutaneous flap. *Br J Plast Surg.* 1979, 32: 12-14.
- 27- Hui K, Lineweaver W. Abdominal wall reconstruction. *Adv Plast Reconstr Surg.* 1997, 14: 213-44.
- 28- Rohrich RJ, Lowe JB, Hackney FL, Bowman JL, Hobar PC. An algorithm for abdominal wall reconstruction. *Plast Reconstr Surg.* 2000, 105: 202-16.
- 29- Mathes SJ, Bostwick III, J. A rectus abdominis myocutaneous flap to reconstruct abdominal wall defects. *Br J Plast Surg.* 1977, 30: 282-83.
- 30- Jacobson WM, Petty PM, Bite U, Johnson GH. Massive abdominal wall hernia reconstruction with expanded external/internal oblique and transversalis musculofascia. *Plast Reconstr Surg.* 1997, 100: 326-35.
- 31- Ramirez OM, Ruas E, Dellon AL. “ Components separation ” method for closure of abdominal - wall

- defects: An anatomic and clinical study. *Plast Reconstr Surg.* 1990, 86: 519-25.
- 32- Chevray PM, Singh NK. Abdominal wall reconstruction with the free tensor fascia lata musculofasciocutaneous flap using intraperitoneal gastroepiploic recipient vessels. *Ann Plast Surg.* 2003, 51: 97-102.
- 33- Depuydt K, Boeckx W, D'Hoore A. The pedicled TFL flap as a salvage procedure for an infected abdominal mesh. *Plast Reconstr Surg.* 1998, 102: 187-90.
- 34- Karakousis CP, Volpe C, Tanski J, Colby ED, Winston J, Driscoll DL. Use of mesh for musculoaponeurotic defects of the abdominal wall in cancer surgery and the risk of bowel fistulas. *J Am Coll Surg.* 1995, 181: 11-16.
- 35- Larson GM, Vandertoll DJ. Approaches to repair of ventral hernia and full thickness losses of the abdominal wall. *Surg Clin N Am.* 1984, 64: 335-49.
- 36- Mathes SJ, Steinwald PM, Foster RD, Hoffman WY, Anthony JP. Complex abdominal wall reconstruction: A comparison of flap and mesh closure. *Ann Surg.* 2000, 232: 586-96.
- 37- Caffee HH. Reconstruction of the abdominal wall by variations of the tensor fascia lata flap. *Plast Reconstr Surg.* 1983, 71: 348-51.
- 38- O'Hare PM, Leonard AG, Brennen MD. Experience with the tensor fasciae latae free flap. *Br J Plast Surg.* 1983, 36: 98-104.
- 39- O'Hare PM, Leonard AG. Reconstruction of major abdominal wall defects using the tensor fasciae latae myocutaneous flap. *Br J Plast Surg.* 1982, 35: 361-66.
- 40- Kimata Y, Uchiyama K, Sekido M, Sakuraba M, Iida H, Nakatsuka T, et al. Anterolateral thigh flap for abdominal wall reconstruction. *Plast Reconstr Surg.* 1999, 103: 1191-97.
- 41- Sharma RK, Sigh G, Naidu PM. Abdominal wall defects: Anatomic classification and a scheme for management. *Ann Plast Surg.* 1998, 41: 180-84.
- 42- Dibbell DG, Jr, Mixer RC, Dibbell DG, sr. Abdominal wall reconstruction ("The mutton chop" flap). *Plast Reconstr Surg.* 1991, 87: 60-65.
- 43- Weinstein LP, Kovachev D, Chaglassian T. Abdominal wall reconstruction. *Scand J Plast Reconstr Surg.* 1986, 20: 109-13.
- 44- Disa JJ, Goldberg NH, Carlton JM, Robertson BC, Slezak S. Restoring abdominal wall integrity in contaminated tissue-deficient wounds using autologous fascia grafts. *Plast Reconstr Surg.* 1998, 101: 979-86.
- 45- Kuo YR, Kuo MH, Lutz BS, Huang YC, Liu YT, Wu SC, et al. One-stage reconstruction of large midline abdominal wall defects using a composite free anterolateral thigh flap with vascularized fascia lata. *Ann Surg.* 2004, 239: 352-58.
- 46- Koshima I, Moriguchi T, Inagawa K, Urushibara K. Dynamic reconstruction of the abdominal wall using a reinnervated free rectus femoris muscle transfer. *Ann Plast Surg.* 1999, 43: 199-203.
- 47- Lowe JB, Garza JR, Bowman JL, Rohrich RJ, Strodel WE. Endoscopically assisted "components separation" for closure of abdominal wall defects. *Plast Reconstr Surg.* 2000, 105: 720-29.
- 48- Lyle WG, Gibbs M, Howdieshell TR. The tensor fascia lata free flap in staged abdominal wall reconstruction after traumatic evisceration. *J Trauma: Injury, Infection, and Critical Care.* 1999, 46: 519-22.
- 49- Bhatena HM, Kavarana NM. One stage reconstruction of extensive abdominal wall defect with bilateral tensor fascia lata (TFL) flaps. *Indian J Cancer.* 1993, 30: 10-15.
- 50- Cederna JP, Davies BW. Total abdominal wall reconstruction. *Ann Plast Surg.* 1990, 25: 65-70.