

Nuclear Morphometry and Ki67 Proliferative Marker in Renal Clear Cell Carcinoma

WAFAA HELMY, M.D.*; GAMAL I. SELMY, M.D.** and ADEL OSSMAN, M.D.*

The Departments of Pathology* and Urology**, Al-Azhar University, Cairo, Egypt.

ABSTRACT

Background and purpose: Different grading systems for renal cell carcinoma (RCC) were proposed to assess patients' outcome. Interobserver variability interfere with the widespread acceptance. Study of the tumor proliferative activity could provide another parameter for predicting biologic aggression and subsequent prognosis.

Patients and Methods: Twenty patients who underwent radical nephrectomy for RCC were selected for histopathologic study. Normal tissue beneath the neoplasm in 5 specimen was used as control. Nuclear morphometry was carried by using CAS 200 image analysis system. Cellular proliferation was examined by immunohistochemistry, using Ki67 (MIB-1) monoclonal antibody on paraffin embedded tissue. All data were subjected to statistical evaluation.

Results: The mean nuclear area was significantly increased versus normal nuclei ($p = 0.0001$). It was significant in relation to patients' survival. There was significant increased nuclear area with advancing stages (means = $51.85 \pm 14.3 \mu\text{m}^2$, $75.50 \pm 12.8 \mu\text{m}^2$ and $116.35 \pm 7.16 \mu\text{m}^2$) and grade III tumors (mean = $116.27 \pm 7.08 \mu\text{m}^2$). There was an insignificant difference between grades I and II ($59.96 \pm 17.16 \mu\text{m}^2$ and $62.34 \pm 20.22 \mu\text{m}^2$ respectively). The mean nuclear diameter was significantly increased with stage IIIa while no difference was noticed between stage I and II ($20.29 \pm 0.92 \mu\text{m}$, $14.31 \pm 2.44 \mu\text{m}$ and $15.33 \pm 1.54 \mu\text{m}$ respectively). Tumor grading was significant in relation to the mean nuclear diameter ($14.3 \pm 2.44 \mu\text{m}$, $15.33 \pm 1.45 \mu\text{m}$ and $20.29 \pm 0.92 \mu\text{m}$). The mean Ki67 (MIB-1) proliferative index (PI) was significantly increased in the tumor versus control region ($p = 0.0001$). Ki67 PI was significant in relation to stage ($9.2 \pm 8.89\%$, $45.98 \pm 4.43\%$ and $58.67 \pm 6.23\%$), ($p = 0.0001$). However, PI was significantly increased with grade III tumors without a significant difference between grade I and II ($p = 0.02$).

Conclusion: Morphometric nuclear area and Ki67 proliferation index could provide reliable information that complements the other parameter to assess tumor prognosis and patients' survival.

Key Words: RCC - Ki67 - Morphometry

INTRODUCTION

Renal cell carcinoma (RCC) is a tumor with several histologic distinctive subtypes, related more or less to specific cytogenetic defects [1]. The etiology and histogenesis remain obscure [2].

Three variables seem to determine the prognosis of RCC. These include tumor burden (size and weight of the primary tumor), stage and tumor cell morphology [3,4].

Nuclear morphometry was found to correlate with the nuclear grading and patient's survival [5,6]. The most frequently used grading systems were proposed by Skinner et al., [7] and Fuhrman et al. [8]. These various systems suffer from problems related to inter-observer variability.

Cellular proliferation rate may provide another predictive variable for biologic aggression of RCC and therefore prognosis. Cellular proliferation rate could be evaluated by study of the S-phase of the cell cycle, Ki67 antigen and proliferating cell nuclear antigen (PCNA) [9].

Cell-cycle analysis demonstrated expression of the Ki67 antigen (a proliferative marker) during G1, S, G2 and M phases [10]. In different studies, Ki67 was considered as a good predictive marker for RCC aggression and survival outcome of patients [11,12]. Therefore, the purpose of this study was to assess nuclear grading of RCC on basis of nuclear morphometry in relation to the proliferative activity.

PATIENTS AND METHODS

This study was carried on archival revision of the clinical and pathologic findings of patients

who underwent radical nephrectomy at Al-Azhar University hospitals between 1993 and 1998.

Clinical staging was based on the results of chest radiography, skeletal survey, bone scanning and computed tomography scans (CT scan). Follow-up from the patients' files was recorded. Tumor staging was performed according to the UICC/TNM system (Table 1), described by Reuter and Gaudin [13]. Histopathologic revision evaluated the nephrectomy specimens for the type of primary tumor, surgical resection margins including the renal vein and sinus, ureteric margin and regional lymph nodes to accomplish staging. Tumor grading was classified according to Syrjanen and Hjelt [14] (SH grading) and Furhman [8] (F grading). The criteria used were detailed in Table (2).

Normal renal tissue in 5 specimens was used as control.

Morphometry:

By using CAS 200 image analysis system, the largest nuclear diameter and nuclear area were measured at X 40 objective lens as demonstrated in Figs. (1 & 2). The mean of 5 fields in each case was calculated and compared to different grading systems.

Immunohistochemistry:

According to Shi et al. [15], 5 μm sections were prepared on adhesive slides. After deparaffinization and rehydration, antigen retrieval was performed. After thorough wash in deionized water, sections were immersed in phosphate buffer saline (PBS), pH 7.2. The labeled streptavidin-biotin-peroxidase technique was undertaken with the monoclonal antibody MIB-1 directed against the Ki67 antigen. Negative controls prepared by substitution of non immune serum on sections and known positive controls were run in parallel to give reliable results. Color was developed by using the DAB chromogen. Immunoreactivity was identified by nuclear brown color. Quantitation of nuclear positivity was measured by CAS 200 image analysis system. All data were subjected to statistical analysis using ANOVA. Differences were considered significant if p was ≤ 0.05 .

RESULTS

A total of 20 nephrectomy specimens that fulfilled the criteria of the study, were clear cell

variant of RCC (Fig 3). The survival rate of these patients ranged from 8 to 60 months.

Stage I was present in 10 cases (50%), stage II in 6 cases (30%) and stage IIIa in 4 cases (20%). No lymph node metastases were detected in the studied cases. The survival rate significantly correlated to the stage ($p = 0.0001$).

Grade I was seen in 7 cases (35%), grade II in 9 cases (45%) and grade III in 4 cases (20%). The survival rate significantly decreased with grade III ($p = 0.01$), while no significant correlation was detected with grades I and II.

Morphometry:

Table (3) demonstrates the comparison between different stages and grades (F and SH) with the morphometric parameters. There was a significantly increasing grade to stage IIIa, while there was an insignificant difference between grades I and II to stages I and II ($p = 0.003$).

The mean nuclear area was significantly increased with increasing stage ($p = 0.0001$) (Table 3). Stage I had a mean nuclear area of $51.85 \pm 14.3 \mu\text{m}^2$, stage II $75.50 \pm 12.8 \mu\text{m}^2$ and stage 3 $116.35 \pm 7.16 \mu\text{m}^2$.

The mean nuclear diameter was significantly increased with stage III ($p = 0.004$), while an insignificant difference was noticed with stage I or II.

The comparison between tumor grade and morphometric parameters is demonstrated in Table (4). The mean nuclear area was significantly increased with grade III ($p = 0.0001$), while an insignificant correlation was noticed with grades I and II.

Immunohistochemistry:

The expression of the proliferative marker Ki67 was identified by the nuclear reactivity in 16 out of the 20 specimens (80%) (Fig. 4). Comparison between stage and grade of the tumor to the Ki67 marker is demonstrated in Tables (2 & 3). There was a significantly increased proliferation index (PI) with increasing stage ($p = 0.0001$). On the contrary, no significant correlation was noticed with grades I and II ($21.55 \pm 21.1\%$ and $26.82 \pm 21.2\%$ respectively). However, grade III was associated with a significantly increased PI ($58.67 \pm 6.23\%$), ($p = 0.02$).

Fig. (1): Measurement of the largest nuclear diameter and nuclear area in:

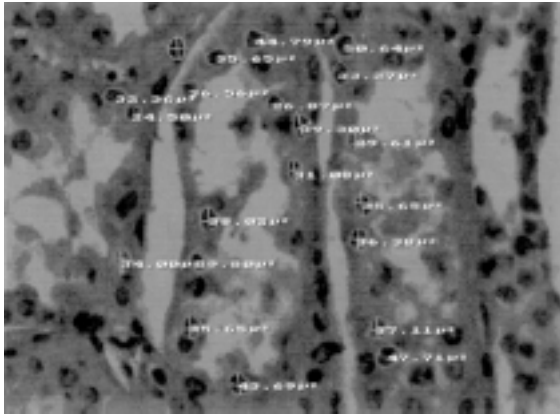


Fig. (1,a): Normal control with mean nuclear diameter = $9.13 \pm 0.83 \mu\text{m}$ and mean area = $40.4 \pm 4.45 \mu\text{m}^2$.

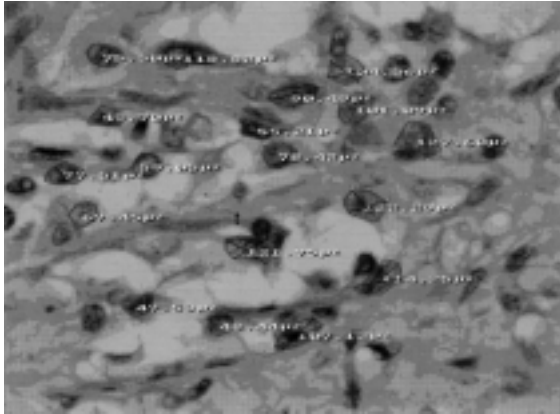


Fig. (1,b): A case of RCC Grade III with mean diameter = $20.29 \pm 0.92 \mu\text{m}$ and mean area = $116.27 \pm 7.08 \mu\text{m}^2$ (CAS 200 image analysis).

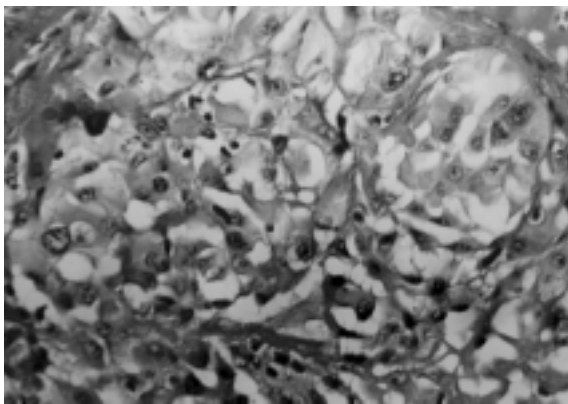


Fig. (2): Renal cell carcinoma grade II (H&E X 200).

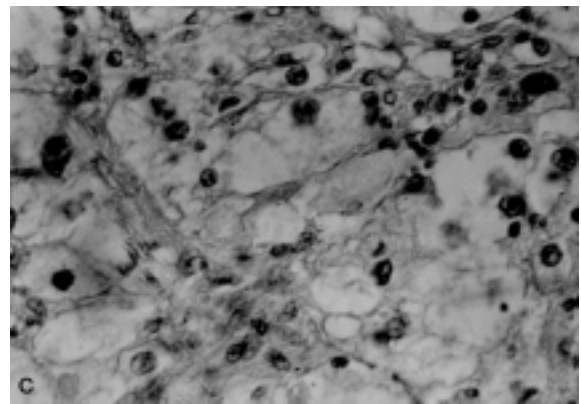
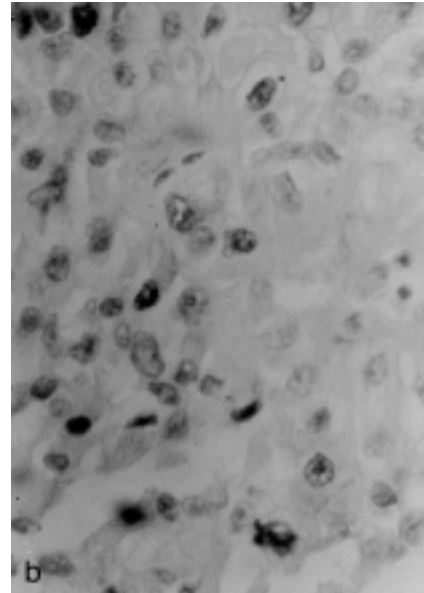
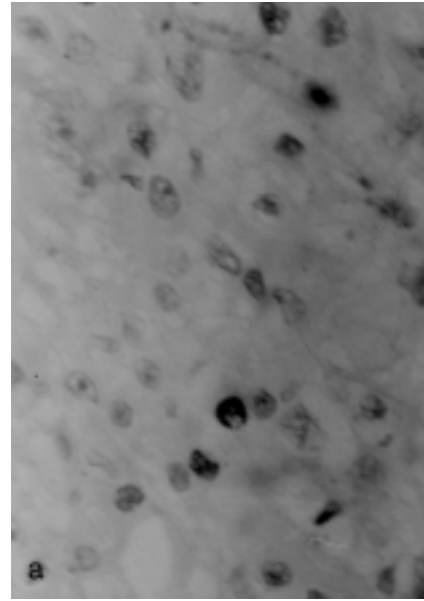


Fig. (3): Nuclear positive reactivity of Ki67 (MIB-1) in renal cell carcinoma, the positive reaction involving the nucleoplasm. a) RCC stage I, grade I with a mean of 9.4% Ki67 expression, b) Stage IIIa, grade II with 45.98% (DAB X 400). c) Stage IIIa grade III with 58.67% (DAB X 300).

Table (1): Staging of renal tumors [13].

Tumor stage	Description
Stage I	Tumor is confined to the kidney < 7 cm size
Stage II	Tumor is confined to the kidney > 7 cm size
Stage III	
A	Extension to perinephric fat within Gerota's fascia
B	Gross tumor in renal vein or vena cava below the diaphragm
C	Gross tumor in vena cava above the diaphragm
Stage IV	Extension of tumor beyond the Gerota's fascia

Table (2): Description of the two common grading systems for renal cell carcinoma.

Grade	Morphologic features
Fuhrman et al., 1982 [8]	
F I	Uniform rounded nuclei Nuclear diameter is 10 μm
FII	Inconspicuous nucleoli Slightly irregular nuclei Nuclear diameter is 15 μm
FIII	Evident nucleoli Very irregular nuclei Nuclear diameter is 20 μm
FIV	Prominent large nucleoli Multilobated bizarre nuclei Nuclear diameter > 20 μm Prominent nuclei and spindle cells often present
Syrjanen & Hjelt 1978 [14]	
SH I	Well differentiated; spherical nuclei with equal size, rare mitosis
SH II	Moderately differentiated, some anisonucleosis and hyperchromasia
SH III	Poorly differentiated, profound anisonucleosis and frequent mitosis

Table (3): Comparison between tumor stage and different parameters.

Stage	Area μm^2	Nuclear diameter μm	Ki 67 expression %	Survival (months)
Normal control (n = 5)	40.4 \pm 4.45	9.13 \pm 0.83	0	—
Stage I (n = 10)	51.85 \pm 14.3	14.31 \pm 2.44	9.2 \pm 8.89	51 \pm 11.04
Stage II (n = 6)	75.50 \pm 12.8	15.33 \pm 1.54	45.98 \pm 4.43	22.67 \pm 2.07
Stage IIIa (n = 4)	116.35 \pm 7.16	20.29 \pm 0.92	58.67 \pm 6.23	10 \pm 2.3
	$p = 0.0001$	$p = 0.004$	$p = 0.0001$	$p = 0.0001$

Table (4): Comparison between F and SH grading system and different parameters.

F and SH grade	Nuclear area μm^2	Nuclear diameter μm	Ki 67 %	Survival duration (months)
Normal control (n = 5)	40.4 \pm 4.45	9.13 \pm 0.83	0	—
Grade I (n = 7)	59.96 \pm 17.16	12.88 \pm 1.22	21.55 \pm 21.1	41.14 \pm 16.76
Grade II (n = 9)	62.34 \pm 20.55	16.02 \pm 1.77	26.82 \pm 21.2	39.78 \pm 17.45
Grade III (n = 4)	116.27 \pm 7.08	20.29 \pm 0.92	58.67 \pm 6.23	10 \pm 2.31
	$p = 0.0001$	$p = 0.0001$	$p = 0.02$	$p = 0.01$

DISCUSSION

Renal cell carcinoma exhibits a wide variation in clinical course, despite the use of conventional prognostic factors as tumor stage and grade to predict the prognosis [16]. There is much evidence to indicate that tumor stage is significantly associated with patient survival [17].

In the present study, 50% of the patients with stage I tumor achieved the 5 year survival, nearly similar to that reported by Reuter & Gaudin [13] and Tossi et al. [18].

Different grading systems were proposed to evaluate and predict the patients' outcome [2,8,14,19,20].

We used the SH grading system for morphometric comparison, since this system was considered to have the least inter-observer variability. Also we used Fuhrman grading system, concerned with the nuclear diameter. However, it is difficult to explain the basis of differences between SH and Fuhrman grading systems [3]. The CAS 200 analysis system, used in our study on H&E stained sections, was easier for application and more accurate in computing the measurements. Computer assisted microscopy was also used to perform nuclear morphometry on Feulgen stained nuclei [4].

The mean nuclear diameters in the present study were parallel to the grading system proposed by Fuhrman et al. [8]; but it was an independent parameter with survival in comparison to tumor stage. In the study of Monge et al., [5] the major nuclear diameter was the significant parameter.

Evaluation of mean nuclear area in the present work correlated well with tumor stage and patients' survival. Our results are in accordance with those reported by Francois et al., [2] and Ozer et al. [21]. The nuclear area was significantly larger in short-term survivors in the study of Tosi et al. [18]. The histologic grade of renal cell carcinoma, particularly the clear cell variant, has been found to be an independent prognostic factor [12].

Evaluation of the biologic behavior of the tumor may provide more predictable information. The positivity rate of Ki67 (MIB-1) in the present study was in parallel to that noticed in the study of Delahunt [17], Tanioka et al., [22] and Tannapfel et al. [12]. The monoclonal antibody (MIB-1) stains the same antigen stained by Ki67 which can be used on paraffin sections, as the Ki67 antigen is preserved only by freezing and lost by standard fixation [23].

From our data, the Ki67 proliferation index significantly correlated with short patients' survival and advanced tumor stage. This was in parallel to the results reported by Tannapfel et al. [12], Delahaunt [17] and Hofmockel et al. [24].

The proliferative index in the present series was significantly increased with increased nuclear area. Nuclei in G2/M (4N) phase of the cell cycle were expanded by the increased DNA mass, where the amount of fluorescence intensity

was twice that of cells in G0/G1 using flow cytometry [25]. During G2/M phases, Ki67 was abundant and located in the nucleoplasm before localizing in the nucleoli [26]. Moch et al., [27] reported that the increased proliferative index may be responsible for the poor prognosis. Ki67 expression was significantly increased with tumor recurrence [16,24]. However, Ki-67 positivity correlated to the tumor grading in urothelial carcinomas of the urinary bladder [28].

In the present study, the reactivity to Ki67 was heterogeneous in the same tumor, which was similar to that noticed in the study of Tannapfel et al. [12]. This heterogeneity in the proliferative turnover of the tumor may be responsible for the morphometric variations and subsequently different grading systems with interobserver variability.

Increased expression of Ki67 in RCC was associated with hyperdiploidy and aberration of chromosome 7, which correlated to the metastatic potential of the tumor [29].

In conclusion: Ki67 (MIB-1) proliferation index is consistent with nuclear area rather than with the mean nuclear diameter. MIB-1 is an easy reliable marker that could be applied on formalin fixed tissue for better assessment of the biologic behavior of renal cell carcinoma and predicting patients' outcome. In addition, the assessment of this proliferation marker will help to reduce interobserver variability which is frequently encountered when using morphometric methods.

REFERENCES

- 1- Bot. F.J., Godschalk K.J.C.T., Krishnadath K.K., Van der Kwast. H.M. and Bosman F.T.: Prognostic factors in renal cell carcinoma: immunohistochemical detection of p53 protein versus clinico-pathological parameters. *Int. J. Cancer.* 1994; 57: 634-637.
- 2- Francois C., Decaestecker C., Petein M., Van Ham P.H., Pelrier A., et al.: Classification strategies for the grading of renal cell carcinomas, based on nuclear morphometry and densitometry. *J. Pathol.*, 1997; 183: 141-150.
- 3- Lanigan D., Conroy R., Barry-Walsh C., Loftus B., Royslen D. and Leader M.A.: Comparative analysis of grading systems in renal adenocarcinoma. *Histopathology*, 1994; 24: 473-476.
- 4- Ruiz-cedra J.L., Herandez M., Gomis F., et al.: Value of deoxyribonucleic acid ploidy and nuclear morphometry for prediction of disease progression in renal cell carcinoma. *J. Urol.* 1996; 155: 459-465.

- 5- Monge J.M., Val Bernal J.F., Buelta L., Garcia-Castrillo L. and Asensio L.: Selective nuclear morphometry as a prognostic factor of survival in renal cell carcinoma. *Histol. Histopathology*. 1999; 14 (1): 119-123.
- 6- Montironi R., Santinelli A., Pomante R., Mazzucchelli R., Colanzi P., Filho A.L. and Scarpelli M.: Morphometric index of adult renal cell carcinoma: comparison with the Fuhrman grading system. *Virchows Arch*. 2000; 437 (1): 82-89.
- 7- Skinner D.G., Colvin R.B., Vermillion C.D., Pfister R.C. and Lead better W.F.: Diagnosis and management of renal cell carcinoma. *Cancer*. 1971; 28: 1165-1177.
- 8- Fuhrman S.A., Lasky L.C. and Limas C.: Pragnostic significance of mophologic parameters in renal cell carcinoma. *Am. J. Surg. Pathol*. 1982; 6: 655-663.
- 9- Nakano E., Kondoh M., Okatani K., Seguchi T. and Sugao H.: Flow cytometric analysis of nuclear DNA content of renal cell carcinoma correlated with histologic and clinical features. *Cancer*. 1993; 72: 1319-1323.
- 10- De-Riese W.T.W, Crabtree W.N., Allhoff E.P., et al: Prognostic significance of Ki-67 Immunostaining in non metastatic renal cell carcinoma. *J. Clin. Oncol*. 1993; (11): 1894-1908.
- 11- Kaiser U., Hansman M.L. and Papdopulos I.: Does the Immunophenotype of renal cell carcinoma correlate with its clinical stage? *Urol. Int*. 1991; 47 (4): 194-198.
- 12- Tannapfel A., Hahn H.A., Katalinic A., Fielkau R.J., Kuhn R. and Wiltekind Ch W.: Prognestic value of ploidy and proliferation markers in renal cell carcinoma. *Cancer*. 1996; 77: 164-171.
- 13- Reuter V.E. and Gaudin P.B.: Adult renal tumors. In: Sternberg SS, ed. *Diagnostic surgical pathology*, 3rd edition, chapter 42, Philadelphia, Lippicott Williams and Wilkins, 1999; pp. 1785-1824.
- 14- Syrjanen K. and Hjelt L.: Grading of human renal adenocarcinoma. *Scand J. Urol. Nephrol*. 1978; 12: 48-55.
- 15- Shi S.R., Key M.C. and Kalera K.: Antigen retrieval in formalin fixed paraffin embedded tissues: An enhancement method for immunohistochemical staining based on microwave overheating of tissue sections. *Am. J. Pathol*. 1991; 140: 835-842.
- 16- Rioux-Leclercq N., Epstein J.I., Bansard J.Y., Turlin B., Patard J.J., Manunta A., Chan T., Ramee M.P., Lobel B. and Moulinoux J.P.: Clinical significance of cell proliferation. Microvessel density and CD44 adhesion molecule expression in renal cell carcinoma. *Human Pathol*. 1996; 32 (11): 1209-15.
- 17- Delahunt B.: Histopathologic prognostic indicators for renal cell carcinoma. *Semin Diagn. Pathol*. 1998; 15 (1): 68-76.
- 18- Tosi P., Luzi P., Baak J.P.A. and Miracco C.: Nuclear morphometry as an important prognostic factors in stage I renal cell carcinoma. *Cancer*. 1986; 58: 2512-2518.
- 19- Hermanek P. and Schrott K.M.: Evaluation of the new tumor, nodes and metastasis. Classification of renal cell carcinoma. *J. Urol*. 1986; 144: 238-242.
- 20- Murphy W.M., Beekwith J.B. and Farrow G.M.: Tumors of the kidney, bladder and related urinary structures. *Atlas of tumor pathology*, 3rd series, Fascicle 2. Washington D.C., Armed Forces Institute of Pathology. 1994; pp. 98-124.
- 21- Ozer E., Yorukoglu K., Sagol O., Mungan U., Demirel D., Tuzel E. and Kirkali Z.: Prognostic significance of nuclear morphometry in renal cell carcinoma. *Br. J. Uol. Int*. 2002; 90 (1): 20-25.
- 22- Tanioka F., Hiroi M., Yamane T. and Hara H.: Proliferating cell nuclear antigen (PCNA), immunostaining and flow cytometry DNA anlysis of renal cell carcinoma. *J. Pathol*. 1993; 139: 185-193.
- 23- Weinberg D.S.: Quantitative immunocytochemistry in pathology. In: Alberto M.M and Peter H.B., eds. *Image Analysis: A Primer for Pathologists*, New York, Raven Press Ltd. 1994; pp. 235-160.
- 24- Hofmokek G., Tsatalpas P., Muller H., Dammrich J., Poot M. and Maurer Schultze B.: Significance of conventional and new prognostic factors for locally confined renal cell carcinoma. *Cancer*. 1995; 67 (2): 296-306.
- 25- Lee S., Tolmachoff T. and Marchevsky A.M.: DNA content analysis (ploidy) by image analysis: Clinical applications and comparison with flow cytometry. In: Alberto M.M and Peter H.B., eds. *Image Analysis: A Primer for Pathologists*. New York, Raven Press Ltd, 1994, pp 261-307.
- 26- Baum H.P., Meurer I., Unteregger G.: Ki67 antigen expression and growth pattern of basal cell carcinomas. *Arch. Dermatol. Res*. 1993; 285: 291-295.
- 27- Moch H., Sauter G., Buchholz N., Gasser T.C., Bubendorf L., Waldman F.M. and Mihatsch M.J.: Epidermal growth factor receptor expression is associated with rapid tumor cell proliferation in renal cell carcinoma. *Hum. Pathol*. 1997; 28 (11): 1255-1259.
- 28- Bol M.G., Baak J.P., Janssen E.A., Breeuwsma N.G. and de Bruin P.C.: Further testing of morphometric grading in T (A,1) urothelial carcinomas of the urinary bladder and the additional value of p53 immunoquantitation. *Anal. Quant. Cytol. Histol*. 2002; 24 (2): 114-120.
- 29- Wada Y., Igawa M., Shiina H., Shigeno K., Yokogi H., Urakami S., Yoneda T. and Maruyama R.: Comparison of chromosomal aberrations detected by fluorescence in situ hybridization with clinical parameters, DNA ploidy and Ki 67 expression in renal cell carcinoma. *Br. J. Cancer*. 1998; 77 (11): 2003-2007.